



Implementing Processing and Feature Extraction of Fundus Images under Diabetic Retinopathy

Dr. Gagandeep Jagdev

Dept. of Computer Science, Punjabi University Guru Kashi College, Damdama Sahib (PB).

***Corresponding Author:** Dr. Gagandeep Jagdev, Dept. of Computer Science, Punjabi University Guru Kashi College, Damdama Sahib (PB).

Abstract: More than ten percent of the patients suffering with diabetes have high risk of eye related issues. DR (Diabetic Retinopathy) is an eye ailment which influences majority of the patients having track record of suffering from diabetes for more than ten years. The paper elaborates on the categories of diabetic retinopathy. The research paper is concerned with pre-processing of raw retinal fundus images using green channel, CLAHE, morphological operation, segmentation, and line tracking.

Keywords: Adaptive histogram equalization (AHE), Contrast limited adaptive histogram equalization (CLAHE), Diabetic Retinopathy (DR), fundus images, Green Channel, segmentation.

Abbreviations: AHE, CLAHE, DM, DR, NPDR, PDR

1. INTRODUCTION

Eye is the main and most sensitive body part which is infected adversely in diabetic persons. Such people suffering from eye disease are said to be suffering from diabetic retinopathy. This happens when high blood levels of sugar cause damage to blood vessels in the retina. The blood vessels either leaks or swells. In worse case, the blood vessels can stop blood from passing through. Often abnormal new blood vessels nurture on retina. All this causes the loss of vision. This disease prevails in people with long history of uncontrolled high blood sugar levels. In initial stages there are only mild vision problems which eventually results in loss of vision [1, 2]. The common symptoms of diabetic retinopathy are abnormal blood vessels, blocked blood vessels, swelling, scarring, leaking of blood vessels, damage to the nerve tissue, changes to the lens, and retinal detachment [3, 4].

The diabetic retinopathy can be classified into two categories mentioned as under.

Non- proliferative diabetic retinopathy (NPDR)

The other name for NPDR is background retinopathy. As the eye does not make new blood vessels during initial stages of diabetic retinopathy, it is called “non-proliferative”. During the initial stages, blood and fluid leak from the damaged blood vessels into the eye. Often the center of the retina begins to swell. This state is often referred as macular edema. The three stages of NPDR are mild, moderate, and severe. The fourth stage is referred as proliferative diabetic retinopathy [5, 6].

Proliferative diabetic retinopathy (PDR)

At this stage, the new blood vessels begin to grow within the retina. These new formed blood vessels are abnormal in size and grow in the center of the eye [7].

AHE (Adaptive histogram equalization) is a computer image processing technique used to improve contrast in images. The most prominent method having been used in diabetic retinopathy is CLAHE (Contrast Limited Adaptive Histogram Equalization). During performing AHE (Adaptive Histogram Equalization) if the region under process has a comparatively small intensity range, as a result of this, the noise in that particular region gets more enhanced. Even some kind of artifacts appear on those regions. To reduce the appearance of such artifacts and noise, AHE undergoes a modification and is called CLAHE [8, 9]. The amount of enhancement in contrast is directly proportional to the slope of

the CDF (Cumulative distributive function) function at that particular intensity level. Hence contrast enhancement is restricted by restricting the slope of the CDF [14]. The height of the histogram at a particular bin determines the slope of the CDF for that bin. Therefore if one limit the height of the histogram to a certain level, the slope of CDF can be limited and hence the amount of contrast can be enhanced. The only difference between AHE and CLAHE is one extra step for clipping the histogram before computing its CDF as the mapping is performed [15]. In the case of CLAHE, the contrast limiting procedure has to be functional for each neighborhood from which a conversion function is derived. Here, like in AHE the transformation function is directly proportional to the CDF of pixels values in neighborhood [10, 11].

2. LITERATURE SURVEY

The diabetic retinopathy affects around two-fifth of the population who identified themselves to have DM [9]. Harding et al. first spotted diabetic retinopathy by scanning the structure of an eye of normal and diabetic patient utilizing ophthalmoscope screening tool. The obtained sensitivity and specificity were 73 and 97 percent respectively [5]. The usual features of the fundus images included the fovea, blood vessels, and optic disc. The key abnormal features included blot hemorrhages and exudates of diabetic retinopathy [6]. Philips et al. first accomplished exudates detection and identification. Three approaches edge detection, thresholding, and classification were deployed for exudates lesions. Global and local thresholding values were utilized for exudates lesions. The specificity and sensitivity were calculated as 71% and 100% respectively [10]. The noteworthy pros found out for single-field fundus photography as clarified by skilled readers is its potential to detect retinopathy. The variation of sensitivity ranges from 61% to 90% and specificity falls under 85 to 97 percent range [11]. The extraction of optical disk boundary is done using red and green channel. The location methodology thrived in 99% of cases. Segmentation algorithm reduced automated segmentations and true OD regions of 86% [12]. Ravishankar et al. proposed a fresh methodology for optic disk detection where the major blood vessels were identified and the bifurcations of these were used to find the approximate location of the optic disk. Number of classifiers have been tested comprising SVM, Fuzzy C-means, Neural Networks, PCA, and simple Bayesian classification [13].

3. CONTRIBUTION VIA IMPLEMENTATION

The implementation phase involves the designing of the GUI interface shown in Fig. 1. Fig. 2 shows the retina image is given as input. Thereafter, the processing is initiated. The input image is converted into Green Channel image. Retina's features or traits can be differentiated by using color as feature descriptor. The green channel generates maximum contrast on retina image, thus differentiating one feature to the other. Green channel shows higher contrast intensity compared with red and blue channel. Thereafter, the image undergoes CLAHE, and morphological operation. The fifth portion of the interface shows the segmented blood vessel image. On pressing the "Edge Detection" button, the sixth portioned portion shows the detected edges and finally on pressing the "Performance Measure" button, the calculated values are displayed in the seventh partitioned portion of the interface.

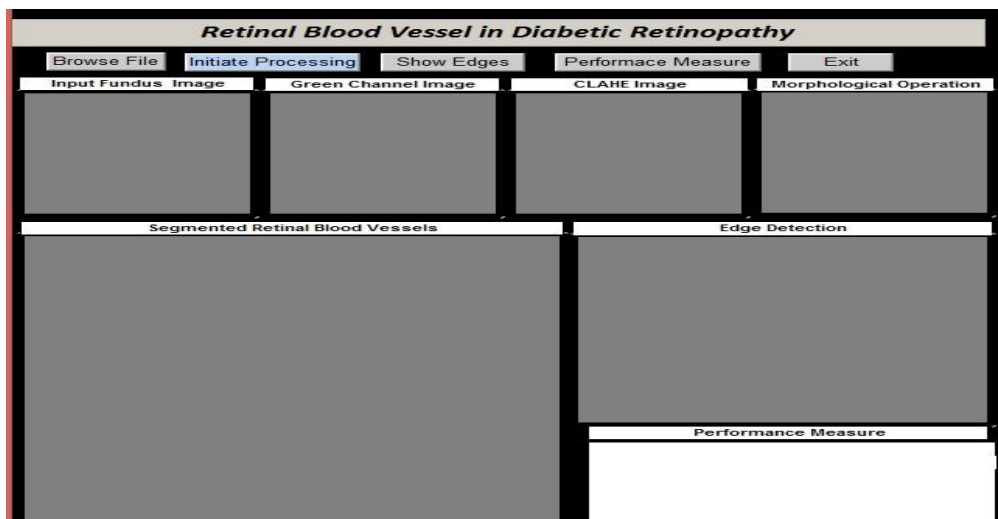


Fig1. The figure shows the designed GUI interface

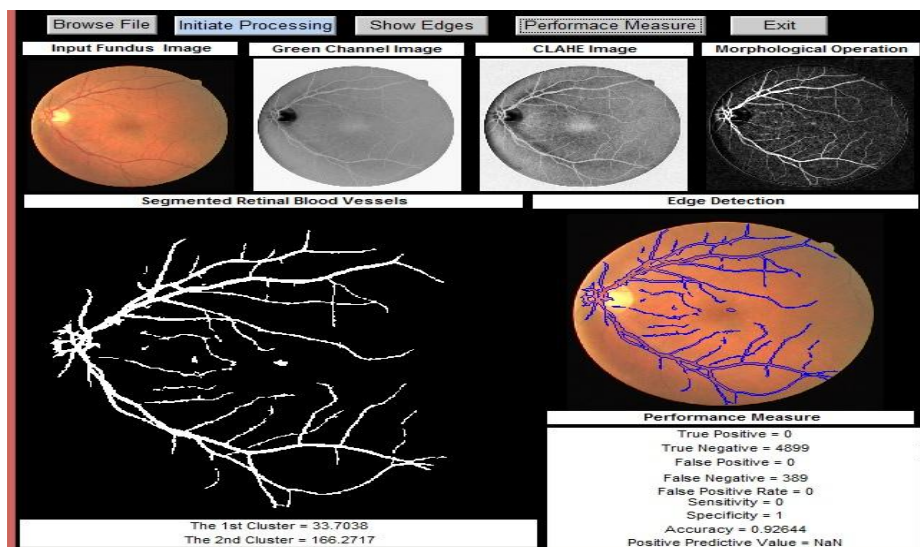


Fig2. The figure shows the GUI interface with appropriate inputs

Fig. 3 shows the GUI interface designed for performing line tracking of the input image. The figure also shows the plotted histogram.

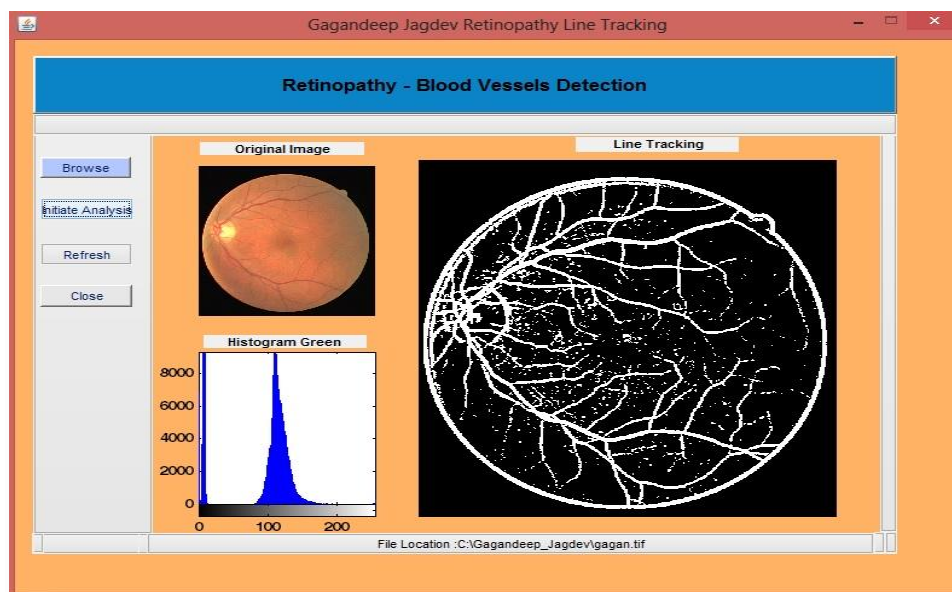


Fig3. The figure shows the GUI interface designed for performing line tracking of the input image

4. CONCLUSION

The research paper discussed that diabetic retinopathy is the effect of DM (diabetic mellitus) to human vision that has resulted in the major cause of blindness. Timely diagnosis of diabetic retinopathy is very important in diabetes treatment. Blood vessel is primary retinal feature which indicates retina pathologies. The paper showed two designed GUI interfaces used for processing fundus images. The first GUI interface performed green channel, CLAHE, morphological operation, segmentation, and edge detection. The second GUI is concerned with line tracking of the input retina image along with plotting histogram.

REFERENCES

- [1] N. B. Prakash and D. Selvathi, "An Efficient Detection System for Screening Glaucoma in Retinal Images," Biomed. Pharmacol. Journal, vol. 10, no. 1, 2017.
- [2] S. S. Rathore and A. Gupta, "A comparative study of feature-ranking and feature subset selection techniques for improved fault prediction," in Proceedings of the 7th India Software Engineering Conference on – ISEC '14, 2014, pp. 1–10.
- [3] D. S. Sisodia and S. Verma, "Image pixel intensity and artificial neural network based method for pattern recognition," World Acad. Sci. Eng. Technol., vol. 57, pp. 742–745, 2011.

- [4] M. Merlin and B. Priestly Shan, "Robust and efficient segmentation of blood vessel in retinal images using gray-level textures features and fuzzy SVM," *Biomed. Pharmacol. J.*, vol. 8, no. 2, pp. 1111–1120, 2015.
- [5] Sisodia D. S, Nair S, Khobragade P. Diabetic Retinal Fundus Images: Preprocessing and Feature Extraction for Early Detection of Diabetic Retinopathy. *Biomed Pharmacol J* 2017;10(2).
- [6] A. Sopharak, B. Uyyanonvara, and S. Barman, "Automatic exudate detection from non-dilated diabetic retinopathy retinal images using Fuzzy C-means clustering," *Sensors*, vol. 9, no. 3, pp. 2148–2161, 2009.
- [7] S. K. and D. M. and D. Santhi, "Effective Segmentation of Optic Disc in Retinal Images for diagnosing Eye Diseases that leads to Blindness," *Biomedical Pharmacol. J.*, vol. 8, no. 1, pp. 427–434, 2015.
- [8] S. P. Harding, D. M. Broadbent, C. Neoh, M. C. White, and J. Vora, "Sensitivity and specificity of photography and direct ophthalmoscopy in screening for sight threatening eye disease: the Liverpool Diabetic Eye Study.," *BMJ*, vol. 311, no. 7013, pp. 1131–5, 1995.
- [9] J. H. Kempen, B. J. O'Colmain, M. C. Leske, S. M. Haffner, R. Klein, S. E. Moss, H. R. Taylor, and R. F. Hamman, "The prevalence of diabetic retinopathy among adults in the United States," *Arch.Ophthalmol.*, vol. 122, no. 4, pp. 552–563, 2004.
- [10] A. Osareh, B. Shadgar, and R. Markham, "A computational-intelligence-based approach for detection of exudates in diabetic retinopathy images," *IEEE Trans. Inf. Technol. Biomed.*, vol. 13, no. 4, pp. 535–545, 2009.
- [11] G. A. Williams, I. U. Scott, J. A. Haller, A. M. Maguire, D. Marcus, and H. R. McDonald, "Single-field fundus photography for diabetic retinopathy screening: A report by the American Academy of Ophthalmology," *Ophthalmology*, vol. 111, no. 5, pp. 1055–1062, 2004.
- [12] I. U. Morphological, E. Detection, A. Aquino, M. E. Gegúndez-arias, and D. Marín, "Detecting the Optic Disc Boundary in Digital Fundus Feature Extraction Techniques," 2010, vol. 29, no. 11, pp. 1860–1869.
- [13] S. Ravishankar, A. Jain, and A. Mittal, "Automated feature extraction for early detection of diabetic retinopathy in fundus images," in *Computer Vision and Pattern ...*, 2009, pp. 210–217.
- [14] T. H. Williamson, "Automatic detection of diabetic retinopathy exudates from non-dilated retinal images using mathematical ... retinal images using mathematical morphology methods," *Comput. Med. Imaging Graph.*, vol. 32(8), no. November 2016, pp. 720–727, 2008.
- [15] A. Sopharak, B. Uyyanonvara, S. Barman, and T. H. Williamson, "Automatic detection of diabetic retinopathy exudates from non-dilated retinal images using mathematical morphology methods," *Comput. Med. Imaging Graph.*, vol. 32, no. 8, pp. 720–727, 2008.

AUTHOR'S BIOGRAPHY



Dr. Gagandeep Jagdev, is a faculty member in Dept. of Computer Science, Punjabi University Guru Kashi College, Damdama Sahib (PB). His total teaching experience is more than 12 years and has 125 international and national publications in reputed journals and conferences to his credit. He is also a member of editorial board of several international peer-reviewed journals and has been active Technical Program Committee member of several international and national conferences conducted by renowned universities and academic institutions. His field of expertise is Big Data, Data Mining, Image processing in Diabetic Retinopathy, ANN, Biometrics, RFID, Cloud Computing, Cloud security, Cryptography, and VANETS.

Citation: Jagdev, G. (2018). *Implementing Processing and Feature Extraction of Fundus Images under Diabetic Retinopathy*. *International Journal of Research Studies in Computer Science and Engineering (IJRSCSE)*, 5(3), pp.34-37. <http://dx.doi.org/10.20431/2349-4859.0503005>

Copyright: © 2018 Authors. This is an open-access article distributed under the terms of the Creative Commons Attribution License, which permits unrestricted use, distribution, and reproduction in any medium, provided the original author and source are credited.