

Study Monitoring and Processing of Onychomycosis in Muslim Peoples and use of Laser Radiation Therapy, Taif, KSA

***Sherifa Mostafa M. Sabra**

Consultant, Asst. Prof., Microbiology Specialty
Micro. Br., Biology Dept., Science College, Taif University, KSA
atheer1800@yahoo.com

Abstract: *This work was resulted of the study monitoring and processing of Onychomycosis (OM) in Muslim Peoples and use of Laser Radiation Therapy (LRT), Taif, KSA. The 1st step was for the prevalence of Toe-Nails-OM (TNs-OM) for the detection of the mean infected micro-organisms (MOs). The 2nd step was the experiment for the LRT use as a topical alternative treatment in fungicidal effects for infected cases by TNs-OM. The 3rd step was for the follow-up of the infected cases by TNs-OM for cure after LRT exposure. The prevalence of positive TNs-OM in suspected cases were 38%. The positive cases were in half-relation to the negative cases, that were at Taif area because of the high-altitude, dry weather and hypo-oxygen conditions which were decrease the growth of MOs. The predominant MOs were isolated from TNs-OM positive cases included *Trichophyton Spp.*, *Candida Spp.*, and *Aspergillus Spp.* The prevalence of TNs-OM cure after LRT of the positive cases under the experiment, were showed in group1 (G1) and group2 (G2) at 1st, 3rd and 5th month after the LRT sessions they had gotten as (47.4, 57.9 and 73.7% for G1), and (52.7, 81.6 and 100% for G2) respectively. There were a differences between G1 and G2 of cases cure as (5.3, 23.7 and 26.3%) respectively. The LRT of 7sessions were more effective on TNs-OM cure than LRT of 5sessions, that was indicated by the cases cure differences between G1 and G2, the cases were completely cure as 100% at 5th month for G2.*

Keywords : *Onychomycosis (OM), Laser Radiation Therapy (LRT), Toe-Nails-OM (TNs-OM), Micro-organisms (MOs), Group1 (G1), Group2 (G2).*

1. INTRODUCTION

OM is a common fungal infection affecting both Finger-Nails (FNs) and TNs which usually caused by Dermatophytes, Yeasts and Moulds^[1]. TNs-OM classified into five clinical types, according to the fungal invasion: Distal and/or Lateral-Subungual (DLSOM), White-Superficial (WSOM), Proximal-Subungual (PSOM), Total-Dystrophic (TDOM), and Candida (COM)^[2]. It tended to affect males more than females and there was a 30 fold increase in adults over children. It was due more commonly to Dermatophytes then Yeasts^[3]. The predominant MOs of TNs-OM were *Trichophyton Spp.*^[4], it affected about (2-10%) of the population, the most common pathology of it was comprising in (18-40%) of all TNs disorders^[5]. It was the major public health problem in many parts of the world, prevalence varied in different geographical areas and with the passing of the time, depend on several factors, especially different environmental and life-style conditions^[6]. It represented up to 50% of all TNs disorders^[7]. It was a common clinical presentation in Iran^[8]. TNs-OM causative MOs were *Trichophyton Spp.*, in 90% of the cases^[9]. It was in diagnosed as 56.8%, positive cultures 74.3%, while positive direct examination 18.2% or just positive culture in 7.5%, which revealed *Candida Spp.* in 61.9%. The most common MOs were *Trichophyton Spp.* 20% and *Aspergillus Spp.* 14.2%. The most common isolates were *Candida Spp.*, Dermatophytes and Moulds^[10]. The exposure of the chromophore to the specific Light wavelength induced the production of harmful radicals, as Reactive Species of Oxygen (ROS) and Nitrogen (RNS), which were capable of killing fungal cells^[11]. Photo Dynamic Inhibition (PDI) or Therapy (PDT) was an alternative approach to anti-fungal medications that primarily target ergosterol production; (which is the most important part in the building of the fungal cell wall). Anti-microbial Photo Dynamic Inhibition (APDI) or Therapy (APDT) combines a pharmacologically inert chromophore, termed a Photo-Sensitizer (PS), with a Light corresponding to the chromophore's specific absorption wavelength^[9]. PDT was another viable alternative for the treatment of TNs-OM. It involved the use of a PS and a Light-source to excite the PS to generate ROS. In-vitro studies had shown the fungicidal properties of PDT with various PS such as: Hypericin

Amino-levulinic Acid (ALA) and Rose Bengal (RB)^[12]. The alternative or emerging treatments for TNs-OM included both Laser and Light treatments as Neodymium-Doped:Yttrium Aluminium Garnet (Nd:YAG) and Diode Lasers (DL) were the treatment options for TNs-OM^[13]. APDT had the ability to kill MOs, had potentially effective against fungal infections^[14], it was effectively inactivates *Trichophyton rubrum*, which was the most common causative agent of TNs-OM^[15]. LRT had been proposed as an alternative option for TNs-OM therapy^[16]. Treatment of TNs-OM by long-pulsed 1064nm Nd:YAG Laser, which resulted in excellent outcome without any severe side effects^[17]. LRT also had the potential to treat patients where systemic anti-fungal were either contraindicated or associated with possible drug-drug interactions^[4]. It resulted in 42.6% of cases were free of TNs-OM after treated by 1064nm Nd:YAG Laser within the 1st cycle and in 66.7% were treated within the 2nd cycle^[18]. Patients infected by TNs-OM received 5 treatment sessions at 4 week intervals with a single follow-up at one month after the final treatment, it was 50% clearance of turbid TNs-OM. Patients with TNs-OM, evaluated a 0.5-ms Nd:YAG Laser, they received 3 treatments directed at a single great TNs-OM and were evaluated at 6 months based on the reduction of turbidity observed in the TNs-OM. In 3 cases the nail was cleared by an area greater than 70%, visible cure was achieved after 6 additional treatments^[19]. Patients in two groups were received (4-8) sessions of Laser treatment with 1 week intervals. The quantify clinical improvement were in group 1 as (63, 62, and 51%), and in group 2 as (68, 67, and 53%), that, it did not find any clear differences between the two groups. The positive were higher at 24 weeks than those at 8 weeks, that indicated rapid recurrence of TNs-OM infection^[20]. By the principle of selective photo-thermo-lysis, based on differences in thermal conductivity, Laser energy may be preferentially absorbed by fungal pathogens resulting in photo-thermal and photo-mechanical damage that spares surrounding human tissues^[21]. An alternate theory suggested the formation of free radicals by incident Laser energy and Light absorption by fungal pigment xantho-megnin, presented in high concentration in *Trichophyton rubrum*^[22]. Physical modalities for TNs-OM, such as LRT, therefore appeared appealing^[23]. PDT offered an alternative treatment for TNs-OM. It had been used as PS with approximately 630nm Light. These modalities were combined with pre-treatment of urea and/or micro-abrasion for better penetration. PDT treatments were tolerated with only mild transient pain, burning and erythema. With further enhancements in PS permeability, decreased pre-treatment and PS incubation times, PDT can be a more efficient and cost-effective in office based treatment for TNs-OM. However, more large-scale randomized control clinical trials were needed to access the efficacy of PDT treatments^[24].

The Aim: It was in three steps which were important and included: The 1st step was for the prevalence of TNs-OM in the Muslim Peoples at Taif area, which was performed for evaluation of the mean etiological MOs and the epidemiological factors. The 2nd step was the experiment for LRT use as a topical alternative treatment in fungicidal effects for positive infected cases by TNs-OM. It was used of long-pulsed 1064nm Nd:YAG Laser sessions with one week interval. Treatment parameters were set with range 35-45J.cm², a spot size of 4mm diameter, pulse duration were 30-35ms, and frequency were 1Hz. The 3rd step was for the follow-up the infected cases by TNs-OM for cure after LRT exposure as an alternative treatment.

2. MATERIALS AND METHODS

Search-Area Selection: It was chosen randomly Dermatology Clinics in the Private Hospitals at Taif area, KSA. The aim was explained to the Hospital Owners, the Dermatologists and the Patients. As well as the works were arranged and started in continue manure with the agreements of them without any signs of the personal data. The cases were collected randomly by the Dermatologists in (No.=200) from Muslim Peoples, (males and females), they were healthy, did not take any medication, age were in (20-70 years). The cases were clinically suspected of TNs-OM infections.

Specimens Collection: For all chosen suspected cases, a technique were used to collect specimens were depended on the site of the infection. DLSOM, the nail clipped short, and a small curette or scalpel blade was used to obtain a specimen from the nail bed as close to the cuticle as possible. A specimen was also taken from the underside of the nail plate. WSOM, a blade or curette was used to scrape the nail surface or the white area, and removed infected debris. PSOM, the healthy nail plate gently pared away with a scalpel blade. A sharp curette was used to remove material from the infected proximal nail bed as close to the lunula as possible. COM, infected material collected from the proximal and lateral nail edges. All specimens collected were labelled and sent to the Micro. Lab. in the ice box within (30-60) minutes^[10].

2.1. Micro. Lab. tests

Microscopical Examination: It was using direct microscopy of the specimens with 20% KOH and Di-methyl Sulfoxide to look for fungal hyphae. If the specimens were examined by KOH and resulted negative, alternately, the specimens can be sent for the Histo-Pathology were using Periodic-Acid-Schiff (PAS) stain and had been found to be a sensitive test for TNs-OM^[18].

Isolation and Identification: For primary isolation, specimens were cultivated in Sabouraud Dextrose Agar (SDA) with and without 0.05% Cyclo-hexamide and 0.005% Chloramphenicol for pathogenic fungi. The culture were incubated at 25-30°C for up to 4weeks and were examined at (2-3) day intervals for fungal growth. Macroscopic and microscopic characteristics were analyzed for genus and *Spp.*, identification, which of the etiological agents performed based on the gross morphology of the fungal colony (texture, color, surface and revers pigment, topography) and microscopic characterization of their hyphae and conidia (type of macro-conidia, shape and size of micro-conidia). In some cases, it was sub-cultured on Potato Dextrose Agar (PDA) or slide cultures and other biochemical tests used final identify. Each sample was inoculated on Dermatophyte Test Media (DTM) and SDA with and without antibiotics and were incubated as per-standard protocol. The cultures were examined twice/1st week and weekly thereafter, for 4weeks. Identification of fungal growth was identified by gross colony morphology on SDA media, Lacto-Phenol Cotton Blue (LPCB) mount, color change on DTM and micro-slide culture^[10, 25].

2.2. Experiment Steps

Gs Under LRT: Positive cases for TNs-OM were in (No.=76) as (38%), they were divided into two Gs each in (No.=38) cases. All cases TNs were treated with long-pulsed 1064nm Nd:YAG Laser sessions with one week interval. Treatment parameters were set with range 35-45J.cm², a spot size of 4mm diameter, pulse duration were 30-35ms, and frequency were 1Hz^[18]. The experiment were under LRT as follow: G1 had gotten 5sessions and G2 had gotten 7sessions.

Gs Follow-Up After LRT: Both Gs of cases were followed-up at 1st, 3rd and 5th month after they had gotten the sessions of each. The watching of the cures were from the etiology of TNs-OM by the clinical signs and the repeated of the mycosis diagnosis.

Data Analysis: The all suspected cases data, the prevalence and the experiment results were recorded. All information were entered into the Microsoft Excel Sheet, then were summarized and analyzed. It was discharged in the tables and the graphs which were observed in clear the work activities^[26].

3. RESULTS AND DISCUSSION

Table1 and graph1. Prevalence of positive *TNs-OM of the suspected cases

Items	Total cases *No.=200	
	Positive *TNs-OM	Negative *TNs-OM
*No.	76	124
*%	38%	62%
*TNs-OM: Toe-Nails Onychomycosis, *No.: Number, *%: Percentage		

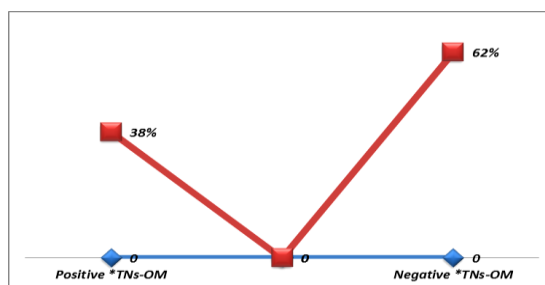


Table1 and graph1 revealed the prevalence of positive TNs-OM of the suspected cases, the results were positive and negative in (38 and 62%) respectively at Taif area for TNs-OM in suspected cases of Muslim Peoples. The positive cases were in half-relation to the negative cases, that were at Taif area because of the high-altitude, dry weather and low oxygen conditions, which were decrease the growth of MOs. The predominant MOs were isolated from TNs-OM positive cases included *Trichophyton Spp.*, *Candida Spp.*, and *Aspergillus Spp.* The predominant MOs of TNs-OM

were *Trichophyton Spp.*^[4], it affected about (2-10%) of the population^[5]. It was the major public health problem in many parts of the world, prevalence varied in different geographical areas and with the passing of the time, depend on several factors, especially different environmental and life-style conditions^[6]. It represented up to 50% of all TNs disorders^[7]. It was a common clinical presentation in Iran^[8]. TNs-OM causative MOs were *Trichophyton Spp.*, in 90% of the cases^[9]. It diagnosed in 56.8%, positive cultures 74.3%, while positive direct examination 18.2% or just positive culture in 7.5%, which revealed *Candida Spp.* in 61.9%. The most common MOs of TNs-OM were *Trichophyton Spp.* and *Aspergillus Spp.* As (20 and 14.2%), the most common isolates were *Candida Spp.*, Dermatophytes and Moulds^[10].

Table2 and graph(2&3). Prevalence of *TNs-OM cure after *LRT of the cases under the experiment

Items	Total *No.=76	Treatment follow-up in *M					
		1 st *M		3 rd *M		5 th *M	
		*No.	*%	*No.	*%	*No.	*%
*G1	38	18	47.4%	22	57.9%	28	73.7%
*G2	38	20	52.7%	31	81.6%	38	100%
Differences		2	5.3%	9	23.7%	10	26.3%

*TNs-OM: Toe-Nails Onychomycosis, *LRT: Laser Radiation Therapy, *No.: Number, *M: Month, *%: Percentage, *G1: Group1, *G2: Group2

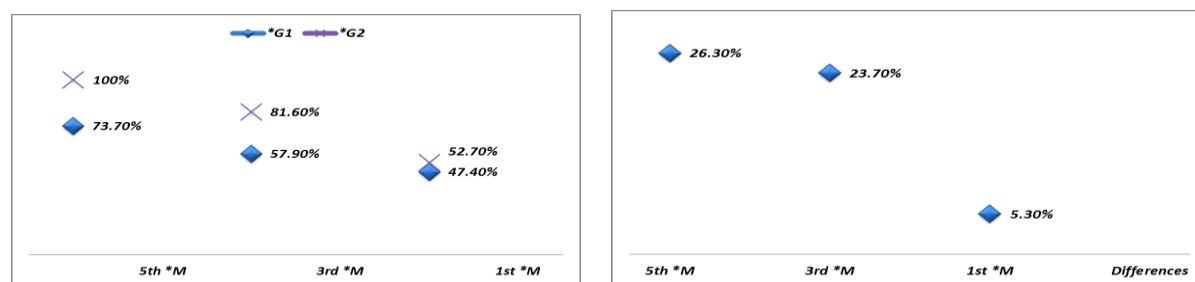


Table2 and graph(2&3) revealed the prevalence of TNs-OM cure after LRT of the cases under the experiment, the results were showed the cases cure in G1 and G2 at 1st, 3rd and 5th month after LRT sessions they had gotten as (47.4, 57.9 and 73.7% for G1), and (52.7, 81.6 and 100% for G2) respectively. There were a differences between G1 and G2 of cases cure as (5.3, 23.7 and 26.3%) respectively. The LRT of 7sessions were more effective on TNs-OM cure than LRT of 5sessions, that was indicated by the cases cure differences between G1 and G2, the cases cure were completely in 100% cure at 5th month for G2. Treatment of TNs-OM by long-pulsed 1064nm Nd:YAG Laser, which resulted in excellent outcome without any severe side effects^[17]. It also had the potential to treat patients where systemic anti-fungal were either contraindicated or associated with possible drug-drug interactions^[4]. PDT was effectively inactivates *Trichophyton rubrum*^[15]. LRT had been proposed as an alternative option for TNs-OM therapy^[16]. It resulted in 42.6% of cases were free of TNs-OM after treated by1064nm Nd:YAG Laser within the 1st cycle and 66.7% were treated within the 2nd cycle^[18]. Patients infected by TNs-OM received 5treatment sessions at 4week intervals with a single follow-up at one month after the final treatment, it was cured in 50%, evaluated a 0.5-ms Nd:YAG Laser, they received 3 treatments directed at a single great TNs-OM and were evaluated at 6months, in 3cases the nail was cleared by an area greater than 70%. Visible cure was achieved in these 3 patients after 6 additional treatments^[19]. The patients were followed-up at 8, 16, and 24 weeks post-treatment. In group1, the effective rate were (63, 62, and 51%), respectively; in group2, (68, 67, and 53%, that, were indicated did not any clear differences between the two groups. It was suggesting relatively rapid recurrence of infection^[20]. An alternate theory suggested the formation of free radicals by incident Laser energy and Light absorption by fungal pigment xantho-megnin, presented in high concentration in *Trichophyton rubrum*^[22]. PDT offered an alternative treatment for TNs-OM. It had been used as PS with approximately 630nm Light. These modalities were combined with pre-treatment of urea and/or micro-abrasion for better penetration. With further enhancements in PS permeability, decreased pre-treatment and PS incubation times, PDT can be a more efficient and cost-effective in office based treatment for TNs-OM. However, more large-scale randomized control clinical trials were needed to access the efficacy of PDT treatments^[24].

4. CONCLUSIONS

The alternative treatments or emerging treatments for TNs-OM included both Laser and Light treatments as Nd:YAG Laser were the excellent treatment options for TNs-OM. The ability of this treatment to kill MOs had potentially effective as anti-fungal infections. The 7sessions were more effective than the 5sessions in the treatment of TNs-OM, which cured 100% of cases also it was revealed clearly from the differences between G1 and G2 of cure percentages.

ACKNOWLEDGMENTS

Many thanks were sent to the Private Hospital Owners, the Dermatologists, the Patients and the Micro. Lab Staffs for their helps in the work steps of the producing this paper work.

REFERENCES

- [1]. Faergemann, J. and Baran, R., 2003. Epidemiology, 1. Clinical presentation and diagnosis of onychomycosis. *Br. J. Dermatology*, 149:1-4.
- [2]. Nandedkar, M. and Escher, R., 2005. An update on disorders of the nails. *J. Am. Acad. Dermatology*, 52:877-877.
- [3]. Foster, K., Ghannoum, M. and Elewski, B., 2004. Epidemiologic surveillance of cutaneous fungal infection in the United States from 1999 to 2002. *J. Am. Acad. Dermatology*, 50:748-752.
- [4]. Gupta, A. and Simpson, F., 2012. Device-based therapies for onychomycosis treatment. *Skin Therapy Lett.*, 17:4-9.
- [5]. Gupta, A. and Humke, S., 2000. The prevalence and management of onychomycosis in diabetic patients. *Eur. J. Dermatology*, 10:379-384.
- [6]. Sigurgeisson, B. and Steingrimsdottir, O., 2004. Risk factors associated with onychomycosis. *J. Eur. Acad. Dermatology Venereology*, 18:48-51.
- [7]. Seebacher, C., Bouchara, J. and Mignon, B., 2008. Updates on the epidemiology of dermatophyte infections. *Mycopathologia*, 166:335-352.
- [8]. Aghamirinia, M. and Ghiasian, S., 2010. Onychomycosis in Iran; epidemiological and causative agent and clinical features. *J. Pn. J. Med. Mycology*, 51:23-29.
- [9]. Dai, T., Fuchs, B. and Coleman, J., 2012. Concepts and principles of photodynamic therapy as an alternative antifungal discovery platform. *Front Micro.*, 3:120-123.
- [10]. Parvaneh, A., Sadegh, K., Shamsi, K., Maryam, G. and Taraneh, R., 2014. Onychomycosis in North-East of Iran. *Iranian J. Micro.*, 6:98-103.
- [11]. Hamblin, M. and Hasan, T., 2004. Photo dynamic therapy: a new antimicrobial approach to infectious disease?. *Photochemical Photo. Sci.*, 3:436-450.
- [12]. Figueiredo, S., Souza, S. and Botelho, A., 2014. Randomized controlled trial comparing photodynamic therapy based on methylene blue dye and fluconazole for toe-nail onychomycosis. *Dermatology Therapy*, 27:43-47.
- [13]. Ledon, J., Savas, J., Franca, K., Chacon, A. and Nouri, K., 2014. Laser and Light therapy for onychomycosis: a systematic review. *Lasers Med. Sci.*, 29:823-829.
- [14]. Krausz, A. and Friedman, J., 2014. News, views, and reviews: antimicrobial photo dynamic therapy: applications beyond skin-cancer. *J. Drugs Dermatology*, 13:624-626.
- [15]. Nenoff, P., Grunewald, S. and Paasch, U., 2014a. Laser therapy of onychomycosis. *J. Dsch. Dermatology Ges.*, 12:33-38.
- [16]. Alster, T. and Lupton, J., 2001. Lasers in dermatology. An overview of types and indications. *Am. J. Cline. Dermatology*, 2:291-303.
- [17]. Hochman, L., 2011. Laser treatment of onychomycosis using a novel 0.65-millisecond pulsed Nd:YAG 1064nm Laser. *J. Cosmetic Laser Therapy*, 13:2-5.
- [18]. Rungsima, W., 2012. The efficacy of 1064 nm Nd:YAG Laser in the treatment of onychomycosis. *J. Laser and Health Academy*, 1:S14.
- [19]. Noguchi, H., Miyata, K., Sugita, T., Hiruma, M. and Hiruma, M., 2013. Treatment of onychomycosis using a 1064 nm Nd:YAG Laser. *Med. Mycology J.*, 54:333-339.

- [20]. Moon, S., Hur, H., Oh, Y., Choi, K., Kim, J., Ko, J. and Ro, Y., 2014. Treatment of onychomycosis with a 1064-nm long-pulsed Nd:YAG Laser. *J. Cosmetic. Laser Therapy*, 16:165-170.
- [21]. Bristow, I., 2014. The effectiveness of Lasers in the treatment of onychomycosis: A systematic review. *J. Foot Ankle Res.*, 7:34-36.
- [22]. Bhatta, A., Huang, X., Keyal, U. and Zhao, J., 2014. Laser treatment for onychomycosis: A review. *Mycoses*, 12:734-740.
- [23]. Lucette, T. and Ted, R., 2015. Laser Therapy for Onychomycosis: Fact or Fiction?. *J. Fungi.*, 1:44-54.
- [24]. Simmons, B., Griffith, R., Falto-Aizpurua, L. and Nouri, K., 2015. An update on photodynamic therapies in the treatment of onychomycosis ,at: <http://www.researchgate.net/publication/270911447.com>
- [26]. Milney, L., Collee, J., Fraser, A., Marmiom, B. and Simmons, A., 2008. Editors. *Fungi In: Mackie and Mc-Cartney, Practical Medical Microbiology*. 14th ed. New Delhi: Churchill Livingstone, pp:697-698.
- [27]. Coulombier, D., Fagan, R., Hathcock, L. and Smith, C., 2001. *Epi Info 6 Version 6.04. A Word Processing, Database and Statistical Program for Public Health*. Centers for Disease Control and Prevention, Atlanta, Delaware, USA.