

## Studies on Henneguyosis Infecting Wild African Catfish, *Clarias Gariepinus* from Behera Governorate, Egypt

Riad H. Khalil, Talaat T. Saad, Mahmoud El-Tanekhy, Hany M.R. Abdel-Latif\*,  
Wafaa S.A. El-Swsaney

Department of Poultry and Fish Diseases, Faculty of Veterinary Medicine, Alexandria University  
Edfina, Egypt

\*Department of Poultry and Fish Diseases, Faculty of Veterinary Medicine, Alexandria University  
Edfina, Behera, Egypt  
healthyfish.20@gmail.com, hmhany@alexu.edu.eg

---

**Abstract:** During a recent investigation of parasites infecting fishes inhabiting different Canals at Behera governorate (Egypt), a total of 200 sharptooth catfish, *Clarias gariepinus* were examined for the presence of Myxosporidian infections. The clinical signs, postmortem lesions, histopathological and parasitological examinations were investigated. It was noted that the infected fish were off food and had respiratory manifestations, sluggish swimming, and congestion of the gills as well as the presence of cyst like structures on the gill filaments, in the cartilage of the accessory breathing organ. Parasitological examinations revealed great numbers of spores in the milky fluid inside the cysts, which identified the presence of plasmodia of *Henneguya branchialis* (Ashmawy *et al.*, 1989) in the gills and accessory respiratory organ of the infected fish. Ultrastructure of *H. branchialis* was successfully identified by scanning electron microscopy (SEM). The prevalence of *H. branchialis* revealed that (20.5 %) of the examined fish were infected. It was also noted that the highest rate of infestation was found in spring and summer seasons and in female specimens more than males.

**Keywords:** *Henneguya* - *Plasmodia* - *Clarias gariepinus* - scanning electron microscopy (SEM).

---

### 1. INTRODUCTION

The African sharptooth catfish, *Clarias gariepinus* (Burchell, 1822) (Siluriformes: Clariidae) is probably the most widely distributed fish species in Africa; it has also many names such as *C. mossambicus* (Peters, 1852) and *C. lazera* (Valenciennes, 1840) that being recognized as its junior synonyms (Skelton, 1993). Its economic importance has been increased markedly in recent years as a result of its extensive use in pisciculture (Skelton and Teugels, 1992).

Myxozoans are considered to be one of the most economically important groups of microscopic metazoan parasites, as they infect food fish. Myxosporidea are almost exclusively fish parasites world-wide (Lom and Dykova, 1994) and have a great importance in ichthyopathology (Sakiti *et al.*, 1990, 1996; Diamant, 1992; Lom and Dyková, 1992; Fomena *et al.*, 1993; Voronin and Chernysheva, 1993 & Eiras, 1994). Some species are very harmful and can weaken or kill their hosts, leading to significant economic losses (Okaeme *et al.*, 1988).

Up to now, 2180 Myxosporean species have been demonstrated to a total of 62 genera that have been established (Lom and Dykov, 2006). In Africa, approximately 200 species of Myxosporidia were identified today, to infect freshwater, brackish and marine fishes (Fomena and Bouix 1997, Kostoingué *et al.*, 2001 & Abakar-Ousman, 2006). Specifically, in Egypt, the fish of river Nile were firstly examined for Myxosporidian parasites by Fahmy *et al.* (1975), then by Abed (1987), Iman *et al.* (1987), Abdel-Ghaffar *et al.* (1995a, b, 1998) and Ali (1998, 1999).

New Myxosporidian pathogens are continually emerging and threatening the development of pisciculture all over the world, and novel species are being described every year (Schlegel *et al.*, 1996), that also parasitize a wide variety of fish tissues and produce pseudocysts that contain hundreds of thousands of small spores.

Among the Myxosporidea, the genus *Henneguya*, which includes at least 126 species (Lom and Dykova, 1992), is one of the most important pathogens of fresh water and marine fishes and mainly

the catfishes. *Henneguya clariae* (Abolarin, 1971) was the first species to be described from the gills of *C. lazera* in Nigeria (Abolarin, 1971). This description also appears to be the first record of the genus *Henneguya* Thélohan, 1892 in Africa. Several years later Landsberg (1987) described *H. laterocapsulata* (Landsberg, 1987) and *H. suprabranchiae* (Landsberg, 1987) from the skin and suprabranchial organs, respectively, of the same host in Israel. Furthermore, *H. branchialis* (Ashmawy et al., 1989) was described from the gills of *C. lazera* in Egypt. Most recently, *H. fusiformis* (Kostoingue, Fall, Faye et Toguebaye, 1999) was described from the gills of *C. anguillaris* in Chad (Kostoingue et al., 1999).

Furthermore, Sabri et al. (2009) had studied the hematological picture of cultured *C. gariepinus* infected with *H. branchialis*. Also, Sabri et al. (2010) had studied the prevalence and histopathological findings of *H. branchialis* in cultured *C. gariepinus* at Ismailia governorate (Egypt). Therefore, the present work was mainly focused to spot light on the prevalence, light and electron microscopic studies of *H. branchialis* and histopathological findings of the infected the sharp-tooth catfish, *Clarias gariepinus* in Egypt.

## 2. MATERIAL AND METHODS

### 2.1. Fish Sampling

A total of two hundred (200) live African catfish (*Clarias gariepinus*) were captured randomly from different Canals at Behera governorate, Egypt and examined for the presence of Myxosporidian infections. Fish specimens of both sexes and with average body weight of 200 to 350 g, were transferred alive in polyethylene bags to the laboratory for further investigation.

Fish specimens were kept in glass aquaria (44 × 38 × 86 cm) with continuous aeration and chlorine free tap water (Innes, 1966) and they were fed on commercial diet pellets containing 30% protein as 3% of the body weight twice a day (Eurell et al., 1978). Further investigations were carried out after 24 hrs of acclimation.

### 2.2. Clinical and Postmortem Examinations

Captured fish were killed using an overdose of tricaine methane sulphate (MS-222), and then clinical examination was performed (Conroy and Hermann, 1981) to determine any clinical abnormalities.

### 2.3. Parasitological Examination

Gills and accessory respiratory organs were exposed and were removed to be examined separately in order to detect and identify the *Henneguya* sp. infections. For permanent preparations, air dried smears from cysts were fixed in absolute methanol and stained with Giemsa (light microscopic examination).

### 2.4. Identification of *Henneguya* Spores

Complete description of the species was prepared according to the guidelines of Lom and Arthur (1989). The spore characteristics such as shape and size of the spores and polar capsules, presence or absence of an intercapsular process and iodophilous vacuole.... etc was taken into consideration. Fresh spores were photomicrographed with an Olympus DP10 digital camera or recorded on videotapes; spores collected were studied and photographed with LOMO microscope. All measurements are given in micrometer.

### 2.5. Scanning Electron Microscopic (SEM) Studies

Cysts were fixed in phosphate buffer 3.5% glutaraldehyde at pH 7.4 for 3-4 hours, post fixed in 1% Osmium tetroxide for 2 hrs, washed in Na-phosphate buffer (pH 7.4). Fixed cysts were gently crushed in phosphate buffer to dislodge the spores that were transferred to glass cover slips which were mounted on copper sluds, gold coated and examined in the EM unit in faculty of Science, Alexandria University, Egypt.

### 2.6. Histopathological Examination

For histopathological examination, some infected portions of the secondary respiratory organ were immediately fixed in 10% neutral phosphate-buffered formalin for at least 24 hrs then processed through the conventional paraffin embedding technique. Sections of 5 µm thickness were stained with

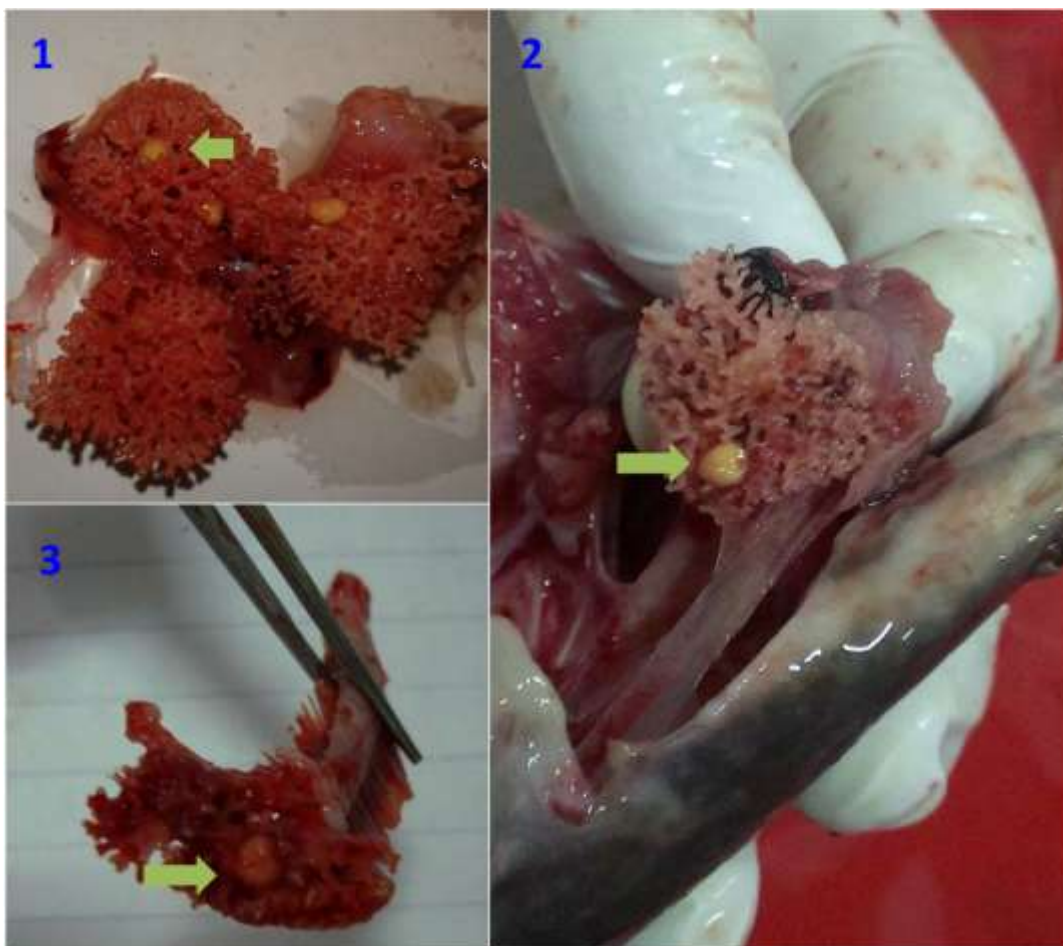
hematoxyline and eosin (H&E) according to the method described by **Culling (1983)** and was examined under light microscope.

### **3. RESULTS AND DISCUSSION**

Henneguyosis is one of the most dangerous diseases, which render the heavily infested fish to be unmarketable, because of the large visible cysts on the gills and the dendritic organs (**Eissa, 2002 & Wagner, 2002**), which are ineligible for consumption according to food hygiene regulations (**Betke et al., 2001**).

#### **3.1. Results of Clinical Examination**

The infected fish were off food and exhibit respiratory manifestations in the form of gasping with rapid opercular movements, sluggish swimming, and congestion of the gills with excessive sliminess. Additionally, Small creamy white cyst structures were found on the gill filaments, the cartilage of the accessory breathing organ (dendritic organs) (**Figs 1 & 2**) (arrows) and in the gill arch (**Fig 3**) (arrow). These cysts were ovoid to round and with different sizes in both sites and the intensity of nodular parasites infection ranged from 3-10 cyst / fish.



**Figs(1-3).** Infected *C. gariepinus* with cysts of *H. branchialis*, yellow cysts were found in the accessory respiratory organ (Figs. 1 & 2) and in the gill arch (Fig. 3).

The respiratory manifestations recorded were occurred as a result of the structural damage and surface inflammation of gills leading to difficulties in osmoregulation and respiration causing decrease in oxygen uptake that causes hypoxia (**Kabata, 1985; Lebelo et al., 2001**) and many other physiological alterations such as reduction in RBCs count and hemoglobin (Hb) value that often cause anemia (**Sabri et al., 2009**).

The presence of these cysts was combined with congestion of the gills with excessive sliminess as inflammatory response of irritations on gills caused by fixation of the parasite (**Meyer, 1968**). All such damages make gills and accessory respiratory organs less functioning by reducing the respiratory surface (**Eissa, 2002 & Sabri et al., 2010**).

### 3.2. Results of Parasitological Examination

*Henneguya Branchialis* (Ashmawy, Abu-Elwafa, Imam and El-Otify, 1989)

**Host:** *Clarias gariepinus* (Burchell, 1822) (Siluriformes: Clariidae).

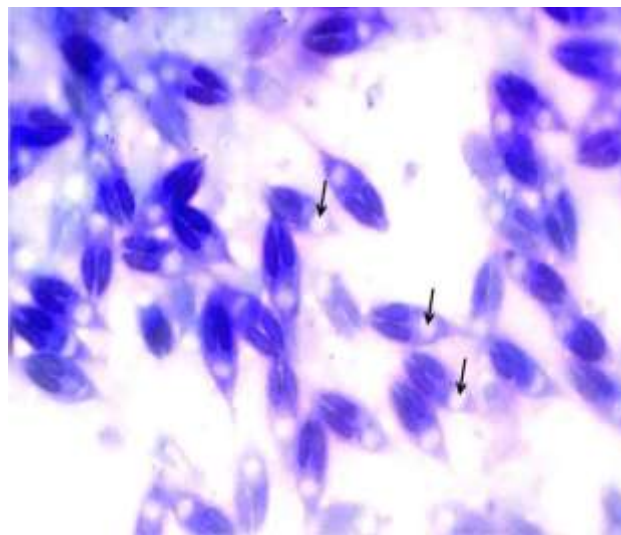
**Site of Infection:** The gills arch and within the tips of cartilage in the accessory breathing organ.

**Locality:** different Canals at Behera governorate, Egypt.

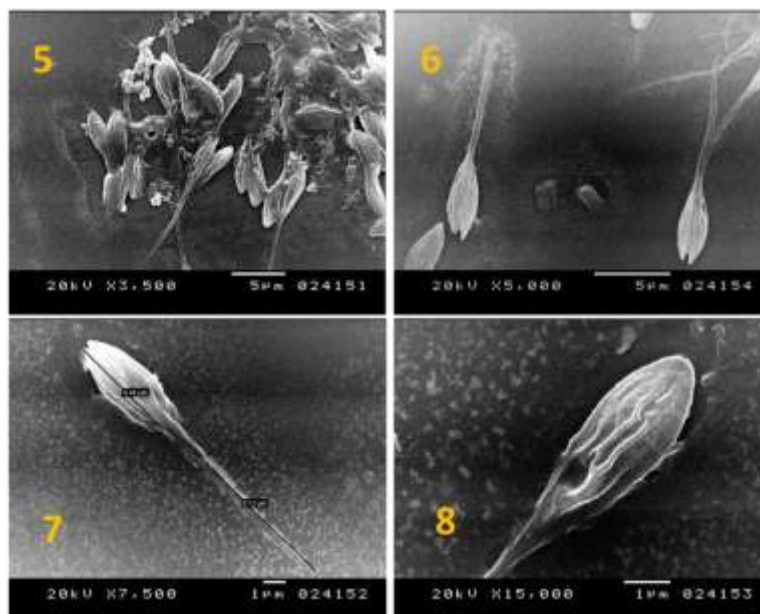
**Prevalence:** 20.5 % (41/200).

**Description:** oocysts were ovoid, whitish and measured 1 to 2 mm. The spore body (Figs. 4 -8) was lanceolate, elongated with anterior end more or less blunt and measured  $14.3 \pm 0.5$  (12-16) x  $5.1 \pm 0.2$  (4-7)  $\mu\text{m}$ .

The two polar capsules were equal, pyriform and measured  $5.7 \pm 0.6$  (4-6) x  $1.4 \pm 0.2$  (1-2)  $\mu\text{m}$ . The polar filaments were not apparent. The sporoplasm was finely granular. The length of the two caudal appendages, which are of equal size, was  $19.1 \pm 0.9$  (18-20)  $\mu\text{m}$ . The total length of the spore was  $33.7 \pm 0.8$  (30-36)  $\mu\text{m}$ .



**Fig4.** Wet mount preparation of *Henneguya* spores from dendritic organ of *C. gariepinus* stained with Giemsa.



**Figs(5-8).** SEM micrograph of mature spores of *Henneguya branchialis*; Fig. (5): SEM micrograph showing the site, size, and shape of *H. branchialis* cyst on the accessory breathing organ of infected *C. gariepinus*, Fig. 6 and 7: SEM micrograph of *H. branchialis* showing the spermatozoa like shape of the parasite. Fig. 8: is an enlarged spore showing the cyst wall, the anterior groove, the posterior groove, and the edges of spore of *H. branchialis*.



### 3.3. Results of Seasonal Prevalence of *H. Branchialis* in Catfish, *C. Gariepinus*

It was noted that about (20.5%) of a total of 200 catfish examined were infested with *H. branchialis*, with seasonal prevalence 8, 30 and 4% in winter, summer and autumn, respectively. The highest rate of infestation (40%) was recorded in spring (Table 1).

**Table1.** Seasonal prevalence of *H. branchialis* in wild catfish *C. gariepinus*

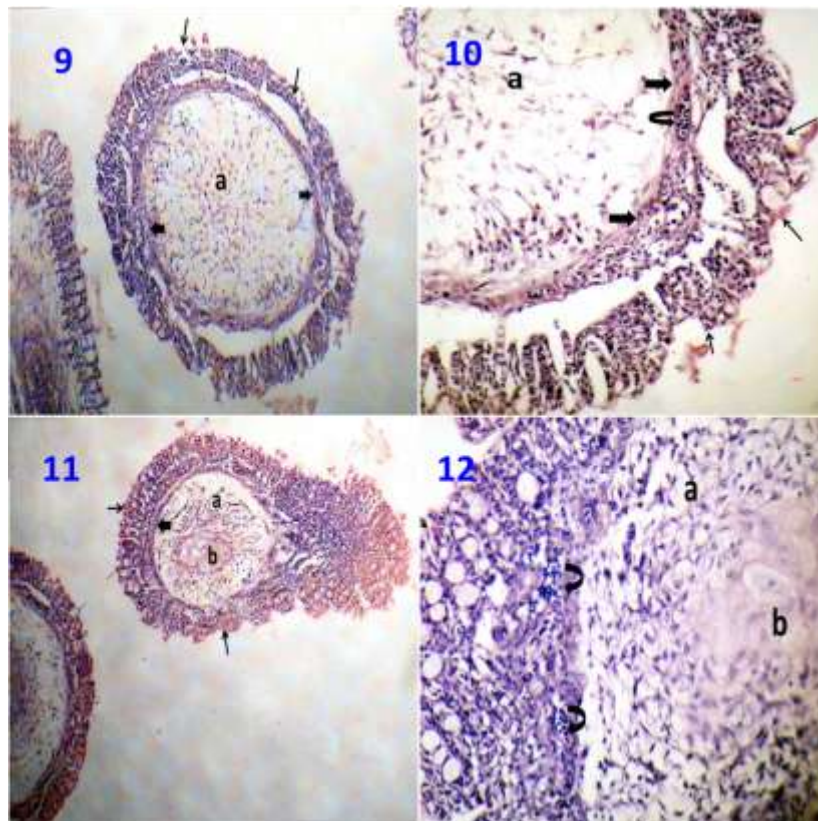
Season	No. of examined fish	Infection percentage	
		No. of infected fish	Percentage %
Spring	50	20	40
Summer	50	15	30
Autumn	50	2	4
Winter	50	4	8
Total	200	41	20.5

The prevalence of the parasite showed seasonal cycle of *H. branchialis* development, as parasite start forming nodules from winter reaching the maximum number in spring then starting decrease by the rupture of the cysts to release the spores in the environment to start infestation.

Seasonal reproductive cycles have also been reported earlier for other species of Henneguya (Molnàr, 1998; Cone, 1994 & Barassa *et al.*, 2003).

It was noted also that the rate of infection with *H. branchialis* was higher in fish specimens with body weight between 220-240 g and in female than in male fish specimens. Higher rate of infestation with Henneguyosis in fish specimens with body weight between 220-240 g and in female fish recorded in the current study has also been reported by Barassa *et al.* (2003).

### 3.4. Results of Histopathological Findings



**Figs(9-12).** Longitudinal sections in the accessory respiratory organ of infected *C. gariepinus* with *H. branchialis* showing plasmodium establishing within a large size habitat within the hyaline cartilage at the tips of the accessory respiratory organ and surrounded with thin layer of connective tissue. The plasmodium containing huge number of *H. branchialis* resulting in pushing and compressing the endothelial cells lining of cartilaginous tissue. Moreover, severe atrophy of the hyaline cartilaginous tissue due to large mass of plasmodium was clearly observed. In addition, dilatation of the blood vessels is seen within the bronchiole epithelium and damage, destruction, sloughing and necrosis of epithelial cells lining were shown.

## REFERENCES

- [1] **Abakar-ousman, L., 2006.** Les Myxosporidies (Myxozoa: Myxosporea) parasites des poissons d'eau douce du Tchad: faunistique et biologie des espèces inféodées à *Oreochromis niloticus* (Linné, 1758) et *Sarotherodon galilaeus* (Linné, 1758) Cichlidae. Thèse de Doctorat/PhD, Université de Yaoundé I, 163 pp.
- [2] **Abdel-Ghaffar, F., Abdel-Aziz, A., Ezz El-Din, N., Naas, S., 1995b.** Light and electron microscopic studies on *Henneguya branchialis* (Ashmawy et al. 1989) (Myxosporea: Myxozoa) infecting the cat fish *Clarias lazera* in the River Nile Egypt. J. Union Arab. Biol. 3 (A):113-133.
- [3] **Abdel-Ghaffar, F., El-Shahawi, G., Naas, S., 1995a.** Myxosporidia infecting some Nile fishes in Egypt. Parasitol. Res. 81:163-166.
- [4] **Abdel-Ghaffar, F., Ibrahim, E.A., Bashtar, A., Ali, M.A., 1998.** Myxosporidia infecting saline and Wadi El Raiyan Lakes, Egypt. J. Egypt Ger. Soc. Zool. 26: 209- 229.
- [5] **Abed, G.H., 1987.** Studies on Myxosporidia of some Nile fishes in Assiut Province. M.Vsc. Thesis. Assiut Univ. Assiut A. R. Egypt.
- [6] **Abolarin, M.O., 1974.** *Myxobolus tilapiae* sp. nov. (Protozoa: Myxosporidia) from three species of freshwater Tilapia in Nigeria. J. West Af. Sci. Assoc. 19: 109–114.
- [7] **Ali, A.A., 1999.** *Henneguya ghaffari* sp. n. (Myxozoa: Myxosporea), infecting the Nile perch *Lates niloticus* (Teleostei: Centropomidae). Dis. Aquat. Org. 38: 225–230.
- [8] **Ali, M.A., 1998.** Light and scanning electron microscopy of *Chloromyxum vanasi* sp. n. (Myxozoa: Myxosporea) infecting gall bladder of the Nile catfish *Bagrus bayad* (Forsk., 1775) (Teleostei: Bagridae). Acta Protozool. 37: 57-61.
- [9] **Ashmawy, K.I., Abu El-Wafa, S.A., Iman, E.A., El-Otify, Y.Z., 1989.** Description of newly recorded Myxosporidian protozoa of freshwater fishes in Behera province, Egypt. J. Egypt Vet. Med. Assoc. 49: 43-53.
- [10] **Barassa, B., Adriano, E., Arana, S., Cordeiro, N.S., 2003.** *Henneguya curvata* sp. n. (Myxosporea: Myxobolidae) parasitizing the gills of *Serrasalmus spilopleura* (Characidae: Serrasalminae) A South American freshwater fish. Folia Parasitol. 50: 151- 153.
- [11] **Betke, P., A. Engelhardt, B. Habedank, E. Schein and S. Thiele, 2001.** Identification of *Henneguya zschokkei* (Gurley, 1894) (Myxosporea: Myxobolidae) in smoked salmon. Archivfurleben Smittel Hygiene Hannover, 52: 100–102.
- [12] **Cone, D.K., 1994.** Annual cycle of *Henneguya doori* (Myxosporea) parasitizing yellow perch (*Perca flavescens*). J. Parasitol. 80: 900– 904.
- [13] **Conroy, D.A., Hermann, L.R., 1981.** Text Book of Fish Diseases. TFH Publications, West Sylvania.
- [14] **Culling, C.F., 1983.** Handbook of histological and histochemical techniques. 3rd ed. London, Boston: Butterworth.
- [15] **Diamant, A., 1992.** A new pathogenic histozoic Myxidium (Myxosporea) in cultured gilt head sea bream (*Sparus aurata*). Bull. Eur. Ass. Fish Pathol. 12: 64-66.
- [16] **Eiras, J.C., 1994.** Elementos de ictioparasitologia. Fundaçao Eng. Antonio de Almeida, Porto.
- [17] **Eissa, I.A.M., 2002.** Parasitic Fish Diseases in Egypt, 1st edition, pp: 52–53. Dar ElNahdda El-Arabia Publishing, Cairo, Egypt.
- [18] **Eurell, T.E., Lewis, S.D., Grumbles, L.C., 1978.** Comparison of selected diagnostic tests for detection of *A. septicemia* in fish. American J. Vet. Res. 39: 1384–1386.
- [19] **Fahmy, M.A., Mandour, A.M., El-Naffar, M.K., 1975.** A survey of Myxosporidia of freshwater (fish) collected from the river Nile at Assiut province. J. Egypt Soc. Parasitol. 4/5: 93-102.
- [20] **Fomena, A., Bouix, G., 1997.** Myxosporea (Protozoa: Myxozoa) of freshwater fishes in Africa: Keys to genera and species. Syst. Parasitol. 37: 161-178.
- [21] **Fomena, A., Marques, A., Bouix, G., 1993.** Myxosporidea (Myxozoa) of *Oreochromis niloticus* (Linnaeus, 1757) (Teleost, Cichlidae) in fish-farming pools at Melen (Yaoundé, Cameroon, Central Africa). J. Afr. Zool. 107: 45-56.

- [22] **Iman, E.A., Ramadan, E.L., Derhalli, F.S., 1987.** On some internal protozoa infecting some Nile fishes in Egypt. J. Egypt. Vet. Med. Assoc. 47: 55-61.
- [23] **Innes, W.T., 1966.** Exotic Aquarium Fishes, 9th edition. Aquarium Incorporated, New Jersey.
- [24] **Kabata, Z., 1985.** Parasites and Diseases of Fish Cultured in the Tropics, 1st edition. Taylor Francis, International Development Research Centre, Philadelphia, London.
- [25] **Kostoïngue, B., Diebakate, C., Faye, N., Toguebaye, B.S., 2001.** Presence of Myxosporidea (Myxozoa: Myxosporea) of the genus *Henneguya* Thélohan, 1892 in freshwater fishes from Chad (Central Africa). Acta Protozool. 40: 117–123.
- [26] **Kostoïngue, B., Fall, M., Faye, N., Toguebaye, B.S., 1999.** Three new myxosporidian (Myxozoa: Myxosporea) parasites of freshwater fishes from Chad (Central Africa). Acta Protozool. 38: 323-326.
- [27] **Landsberg, J.H., 1987.** Myxosporean parasites of the Catfish, *Clarias lazera* (Valenciennes). Systematic Parasitology, 9: 73-81.
- [28] **Lebelo, S.L., Saunders, D.K., Crawford, T.G., 2001.** Observations on blood viscosity in striped bass, *Morone saxatilis* (Walbaum), associated with fish hatchery conditions. Kansas Acad. Sci. 104: 183–194.
- [29] **Lom, J., Arthur, J.R., 1989.** A guideline for the preparation of species description in myxosporea. J. Fish Dis. 12: 151–156.
- [30] **Lom, J., Dyková, I., 1992.** Protozoan Parasites of Fishes. Development in aquaculture and fisheries science 26, Elsevier, Amsterdam.
- [31] **Lom, J., Dyková, I., 1994.** Protozoan Parasites of Fishes, pp: 159–235. Elsevier Science Publishers B.V., Amsterdam, the Netherlands.
- [32] **Lom, J., Dyková, I., 2006.** Myxozoan genera: Definition and notes on taxonomy, Life-cycle terminology and pathogenic species. Folia Parasitol. 53: 1-36.
- [33] **Molnàr, K., 1998.** Taxonomic problems, seasonality and histopathology of *Henneguya creplini* infection of pikeperch *Stizostedion lucioperca* in Lake Balaton. Folia Parasitolog. 45: 261–269.
- [34] **Okaeme, A.N., Obiekezie, A.I., Lehman, J., Antal, E.E., Madu, C.T., 1988.** Parasites and diseases of cultured fish of lake Kainji area Nigeria. Journal of Fish Biology 32: 479-481.
- [35] **Sabri, D.M., El-Danasoury, M.A., Eissa, I.A.M., Khouaiba, H.M., 2009.** Impact of Henneguyosis on Hematoogical Parameters of Catfish (*Clarias gariepinus*). Int. J. Agric. Biol. 11: 228– 230.
- [36] **Sabri, D.M., I.A.M. Eissa, M.A. Danasoury and H.M. Khouraiiba, 2010.** Prevalence of *Henneguya branchialis* in catfish (*Clarias gariepinus*) in Ismailia, Egypt. Int. J. Agric. Biol., 12: 897–900.
- [37] **Sakiti, G.N., Blanc, E., Marques, A., Bouix, G., 1990.** Pathology of protozoan parasites on the gill arches of cichlid fish in Benin (West Africa). Bull. Eur. Assoc. Fish Pathol. 10: 81-83.
- [38] **Sakiti, N., Tarer, V., Jacquemin, D., Marques, A., 1996.** Présence en Méditerranée occidentale d'une Myxosporidie histozoïque pathogène dans les élevages de la Daurade. *Sparus aurata* L. Ann. Sci. Nat., Zool. (Paris) 17: 123-127.
- [39] **Schlegel, M., Lom, J., Stechmann, A., Bernhard, D., Leipe, D., Dykova, I., Sogin, M., 1996.** Phylogenetic analysis of complete small subunit ribosomal RNA coding region of *Myxidium lieberkuehni*: evidence that Myxozoa are Metazoa and related to Bilateria. Arch. Protistenkd. 147: 1–9.
- [40] **Skelton, P., 1993.** A Complete Guide to the Fresh Water Fishes of Southern Africa, p: 388. Southern Book Publishers, Halfway House, South Africa.
- [41] **Skelton, P., Teugels, G.G., 1992.** Neotype description for the African catfish *Clarias gariepinus* (Burchell, 1882) (Pisces: Siluroidei: Clariidae). Ichthyol. Bull. 56: 1–7.
- [42] **Voronin, V.N., Chernysheva, N.B., 1993.** An intracellular gill parasite as possible causative agent of mortality during swim-bladder inflammation in common carp, *Cyprinus carpio* L. J. Fish Dis. 16: 609-611.
- [43] **Wagner, E., 2002.** Identification of *Henneguya salminicola* in mountain white fish in the longan river Utah. Ichtyogram, 13: 4–6.

## AUTHORS' BIOGRAPHY



**Riad H. Khali**, is a senior professor of Fish diseases, Department of Poultry and Fish diseases, Faculty of Veterinary medicine in Alexandria University. He has over 15 years working experience fish microbiologist and research focusing on fish diseases and water resource management. He has contributed more than 75 articles in local and international scientific journals and has supervised 45 PhD and 85 master students.



**Talaat T. Saad**, is associate professor of Fish diseases, Department of Poultry and Fish diseases, Faculty of Veterinary medicine in Alexandria University. He has published more than 60 papers in reputed journals.



**Mahmoud T. Amer**, is a lecturer of Fish diseases, Department of Poultry and Fish diseases, Faculty of Veterinary medicine in Alexandria University. He has published more than 20 papers in reputed journals.



**Hany M. R. Abdel-Latif**, has completed his PhD at the age of 28 years from Alexandria University and postdoctoral studies from Michigan State University School of Veterinary Medicine. He is a Senior Lecturer of Fish diseases, Department of Poultry and Fish diseases, Faculty of Veterinary medicine in Alexandria University. He has published more than 11 papers in reputed journals.



**Wafaa Salah Ali El-Swsaney**, has born 1<sup>st</sup> September 1991 - in Damanhur city, El-Behira governorate, Egypt. She has graduated from Faculty of Veterinary Medicine, Alexandria University (2013) with a general grade (Very Good).