

Branchiomyces Demigrans Infection in Farm-Reared Common Carp (*Cyprinus Carpio L.*) and Nile Tilapia (*Oreochromis Niloticus*) at Different Localities in Egypt, With Special Emphasis to the Role of Environmental Stress Factors

Riad H. Khalil, Talaat T. Saad, Talal A. M. Abo Selema, Hany M. R. Abdel-Latif *

Department of Poultry and Fish Diseases, Faculty of Veterinary Medicine,
Alexandria University, Edfina, Egypt

* Corresponding author: Department of Poultry and Fish Diseases, Faculty of Veterinary Medicine,
Alexandria University, Edfina, Behera, Egypt.

Abstract: Several cases of branchial mycosis caused by *Branchiomyces* spp. were identified in fingerlings specimens of Nile tilapia (*Oreochromis niloticus*) and Common carp (*Cyprinus carpio*) which obtained from different 4 private farms at Damietta, Port-said, El-Behera and Kafr-El Sheikh governorates, Egypt during the summer of 2014. Mortalities ranged from a few hundred to several thousand fish per pond. Significant gross and histopathological findings from these cases were limited to the gills. The infected fishes were suffering from respiratory distress; gasping air from the water surface and rapid movement of opercula. Squash preparations from the infected gill tissue revealed brown, broad, branched and non-septated hyphae. On Sabouraud's dextrose agar (SDA) media with 10% duck decoction showed bright white colonies after 2 days which reached its maximum growth 8 days post inoculation. Microscopical examination of stained growth with lactophenol cotton blue, branched hyphae at their tips were identified which were characteristic for *Branchiomyces* sp. The causal pathogen was identified as *Branchiomyces demigrans*, in which the diameter of spores and non-septated hyphae were 4-10µm and 16-24µm respectively. Histopathological examination from infected fish gills revealed that all examined fishes had fungal mycelia that were mainly but not entirely confined to the base of the primary lamellae and the gill arches. These fungal hyphae were intravascular and occluded vessels in the gill tissues. It was found that ammonia, nitrite and organic matter were elevated over the permissible levels in the surveyed localities. The present paper describes the fungal characteristics and pathology of branchial mycosis caused by *Branchiomyces* spp. in these freshwater fishes and the relation of *Branchiomyces* infection with water quality parameters.

Keywords: *Branchiomyces demigrans* - branchial mycosis - Lactophenol cotton blue

1. INTRODUCTION

The importance of fungal diseases in freshwater fish not stopped only for incidence of mortalities but also as economic importance such as decrease growth rate, hatchability in chronic infection or by mycotoxins production by contaminated fungus in case of bad storage feed (**Lightner et al., 1988**).

In Mycotic affections we should recognize a multiplicity of factors and should include appropriate quality control measures for water quality parameters (temperature, dissolved oxygen, nitrogenous wastes, etc.) as well as bacterial and other contaminants that may confound bioassay results and their interpretation (**Ali, 2005**).

Branchiomycosis is a much feared fungal disease of fishes almost all over the world, especially on carp farms and other fish farm (**Svobodová and Vykusová, 1991**). This fungal disease, sometimes called gill rot, which has caused acute, often high mortality in a number of fresh water fish (**Post, 1987; Klinger and Francis-Floyd, 1996; Durborow et al., 2003 & Judy, 2008**). The disease occurs most frequently in the warm climatic regions (**Ramaiah, 2006**). The rise, and course of the disease depend on factors that underline them; water temperature is one of the factors that play the most important part with a high load of organic matter, ponds fertilized by organic manure, and high levels

of unionized ammonia in the water increase the incidence of fungal gill rot due to gill epithelial cell hyperplasia (Saint-Erne, 2008).

Branchiomycosis is caused by two species; *Branchiomyces sanguinis* in carp and / or tench, crucian carp and sticklebacks and *Branchiomyces demigrans*, which infects large-mouth bass, northern pike, tench and striped bass in Europe, Taiwan, or the USA (Post, 1987; Noga, 1996; Klinger and Francis-Floyd, 1996; Chalmers, 2003 & Judy, 2008).

Branchiomyces sanguinis is generally located in the blood vessels of the gill arch and gill filaments. The diameter of the hyphae is 8–20 µm, the thickness of the hyphawall is 0.2 µm and the diameter of the spore is 5–9 µm while *Branchiomyces demigrans* produces hyphae which are able to penetrate into the gill filaments and spread on their surface. The diameter of the hyphae usually is 13–14 µm and may be up to 22–28 µm at the end of the hypha. The thickness of the wall is 0.5–0.7 µm and the diameter of the spore is 12–17 µm (Svobodová and Vykusová, 1991).

There is no treatment for Branchiomycosis and surviving fish are carriers of the infection and should not be transferred into *Branchiomyces*-free geographical areas. Dead affected fish should be burned and/or buried (Lio-Po and Lim, 2002 & Chalmers, 2003).

Therefore, the present study was aimed for isolation and identification of the causative agent of Branchiomycosis by cultivation on culture media and histopathology study of the affected fingerlings specimens of Nile tilapia (*Oreochromis niloticus*) and Common carp (*Cyprinus carpio*) which obtained from different 4 private farms at Damietta, Port-said, El-Behera and Kafr-El Sheikh governorates, Egypt.

2. MATERIAL AND METHODS

2.1. Examined Infected Fish Specimens

In our investigation, a total number of one hundred and twenty (120) freshwater fish specimens of different sizes and weights; sixty (60) of Nile tilapia (*Oreochromis niloticus*) (120 ± 5 g) and sixty (60) of Common carp (*Cyprinus carpio*) (250 ± 5 g) were obtained from different 4 private farms at Damietta, Port-said, El-Behera and Kafr-El Sheikh governorates, Egypt during the summer of 2014, were transported to the laboratory of the Department of Poultry and Fish diseases, faculty of Veterinary Medicine, Alexandria University as soon as possible. The freshly dead fish specimens were subjected to full clinical signs, postmortem (PM) lesions and mycological examination in addition to histopathological study.

2.2. Clinical Examination

The clinical examination of collected fish was performed according to Amlacher (1970) and Austin and Austin (1987). Autopsy was carried out on the freshly dead and moribund fish according to the method described by Plumb and Bowser (1982). Gills examination was done by lifting the operculum and examined with naked eye. Gills from both side are kept in a Petri dish with little amount of normal saline 90 % then this gill were examined under a dissecting microscope. A wet mount of gill filaments were prepared and examine under a light microscope for detection of spores and hyphae as mentioned by (Chien et al., 1978 & Yanong, 2003).

2.3. Mycological Examination of the Samples

2.3.1. Culture Conditions

The fish surface was disinfected with a swab of cotton moistened with 70% ethyl alcohol (Amlacher, 1970). All positive samples by direct microscopically examination were cultured on Sabouraud's dextrose agar (SDA) (65 g) with cyclohexamide (0.5 g), chloramphenicol (1 x 250 mg capsule), gentamycin (0.65 ml of 40 mg / ml), yeast extract (5 g), 10% duck excrement decoction, 10% gelatin, 0.1% citric acid and distilled water 1000 ml (adjusted pH to 5.8). The inoculated plates were incubated at 25- 28 °C for 5-10 days. Negative plates were not discarded before 2 weeks (Feingold and Baron, 1986).

All the positive mould cultures were purified by sub-culturing on SDA plates, incubated at 25-28 °C for 3-5 days (Ellis, 1971). Lactophenol cotton blue stain (Leaner and Carey, 1978) was applied, for examination of fungal growth on microscopic slide. The shape and diameter of hyphae and spores isolated fungus were measured.

***Branchiomyces Demigrans* Infection in Farm-Reared Common Carp (*Cyprinus Carpio L.*) and Nile Tilapia (*Oreochromis Niloticus*) at Different Localities in Egypt, With Special Emphasis to the Role of Environmental Stress Factors**

2.3.2. Identification of Mould

This was carried out according to the methods of **Refai et al. (1987)**, whereas, All the purified mould cultures were examined for macro and micro-morphological characteristics. The gross morphological examination included the rate of the fungal growth, texture, changes in color during growth, final color of the surface and reverse sides of the colonies were done.

2.4. Histopathological Studies

Following complete necropsy of the freshly dead fish specimens were collected from the gills for histopathological examination. Thereafter, these specimens were rapidly fixed in 10% natural formalin buffered phosphate for at least 24 hours, after that the specimens washed by running tap water then dehydrated through ascending grads of ethanol, cleaning in by chloroform and embedded in paraffin wax at 60 °C. Paraffin block were prepared and from which 5 microns thick sections were obtained by microtome. These sections were stained by Hematoxylin and eosin stain (H & E) (**Roberts, 2001**).

2.5. Assessment of Physico-Chemical Water Properties

Four representative water samples were taken from different areas and depths, were succumbed to physico-chemical analysis. Clean, dry screw capped plastic bottle of one litter capacity previously rinsed several times by distilled water for collecting the samples were used. The tools used for determination of Physico-chemical properties of water quality were namely; Dissolved Oxygen meter for measuring the level of Dissolved oxygen in the water, Salinometer for measuring of % of water salinity, PH meter for measuring the pH values and Kits for measuring the levels of unionized ammonia and Sulphate in the water (**USA, Virginia Company, lot. No .201134**).

3. RESULTS

3.1. Results of Clinical Examination

The affected fish manifested by appearance of respiratory disorders which include lethargy with gulping air at the water surface and rapid movement of operculum, with high mortality rate. At postmortem examination there was no any abnormality on the surface of the morbid fish, while in the examined gills, the affected areas of gills were appeared that striated or marbled appearance with the pale areas representing the infection and the dying tissues and then become necrotizing as in (**Plate 1**).

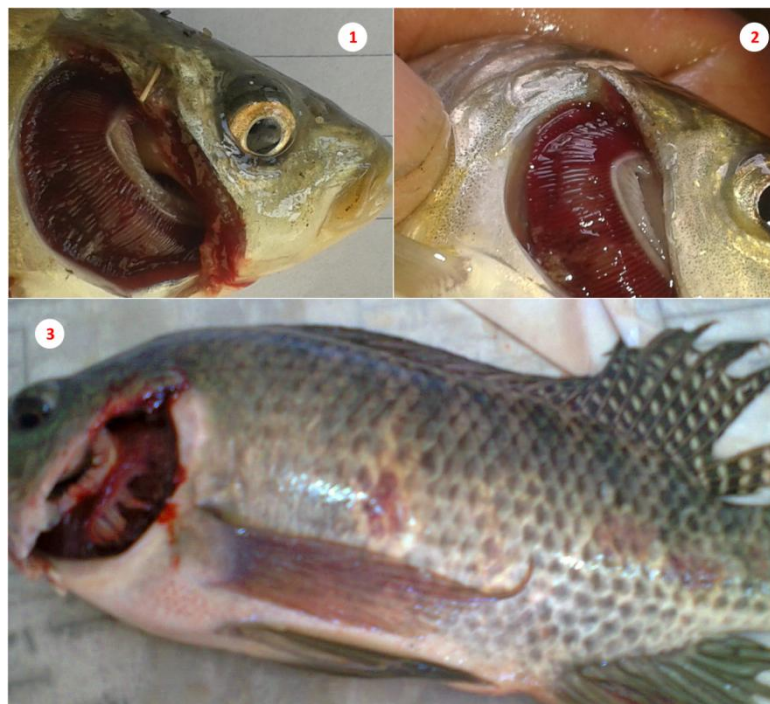

Plate1: Naturally examined *C. carpio* showing marbled appearance of the gills with the pale and necrotizing areas (**Photos 1 and 2**), and congestion and mottled gills of *O. niloticus* (**Photo 3**).

3.2. Results of Mycological Examination

The positive samples by direct microscopic examination were cultured on the specific media and daily examined for fungal growth. The primary growth was appeared after 3 days of culturing and the typical full growth of colonies were observed 7 days of culturing. The typical colonies appear as folded heaped, glabrous and velvety, white in color and with white –yellowish in revers site. The diameter of the hyphae is 12 – 20 μm with spores ranging 5-7 μm diameters. The direct examination of the gills which was mounted under light microscope revealed the characteristic spores of *Br. demigrans* (Plate 2).

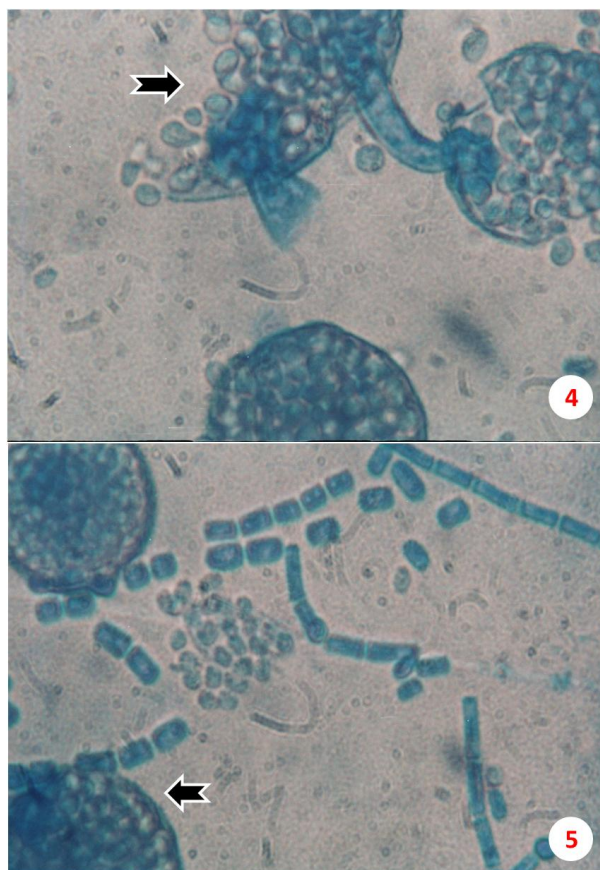


Plate2: Spores and hyphae of *Branchiomyces demigrans*(Photos 4 and 5) stained with Lactophenol cotton blue stain fromcultivation.

3.3. Prevalence (%) of Fungal Infections among Examined Fishes at Different Localities

It was found that 65 % of the examined *O. niloticus* and 87 % of the examined *C. carpio* were infected with *Br. demigrans* (Table 1). The infections were highest in Kafr-El Sheikh governorate among different surveyed localities.

Table1. The prevalence of fungal infections in different fish species (*O. niloticus* and *C. carpio* in different localities

Region	Species	Number of examined samples and positive percentage		
		No. of examined	No. of positive samples	% of infection
Damietta	<i>O. niloticus</i>	15	10	66.67
	<i>C. carpio</i>	15	12	80.00
Port-said	<i>O. niloticus</i>	15	4	26.67
	<i>C. carpio</i>	15	10	66.67
El-Behera	<i>O. niloticus</i>	15	12	80.00
	<i>C. carpio</i>	15	15	100.00
Kafr-El Sheikh	<i>O. niloticus</i>	15	13	86.67
	<i>C. carpio</i>	15	15	100.00
Total	<i>O. niloticus</i>	60	39	65.00
	<i>C. carpio</i>	60	52	86.67

***Branchiomyces Demigrans* Infection in Farm-Reared Common Carp (*Cyprinus Carpio L.*) and Nile Tilapia (*Oreochromis Niloticus*) at Different Localities in Egypt, With Special Emphasis to the Role of Environmental Stress Factors**

3.4. Results of Water Quality Parameters

It was found that ammonia, nitrite and organic matter were elevated over the permissible levels in the surveyed localities (**Table 2**).

Table2. The results of water quality in different farms where naturally infected fish were collected.

Parameters of water quality	El-Behera	Kafr-El Sheikh	Port-said	Damietta	P. L.
D.O. (mg/L)	4.3	4.2	4.5	4.3	6.1
Ammonia (NH ₃) (mg/L)	0.23	0.41	0.19	0.23	0.01
Nitrite (NO ₂) (mg/L)	0.22	0.19	0.31	0.22	0.01
pH	6.2	6.7	6.5	6.2	7.8-8.3
Salinity (PPT)	3	1	2	3	
Organic matter (mg/L)	3.83	3.25	4.11	3.83	2-3

PL: Permissible level (Svobodova *etal.*, 1993).

3.5. Results of Histopathological Examination

3.5.1. Histopathological Findings of the Infected *O. Niloticus*

The Histopathological examination of the infected site of gills of *O. niloticus*(**Plate 3**)showing congestion of blood vessels of primary lamellar epithelium, aneurism, as well as Telangiectasis, whereas the spores and hyphae in the blood vessels of the gill were cause blockage, hemostasis and thrombosis, which consequently caused extensive necrosis of the gill filaments and areas of the gill filaments turned brown (**Photo 6**) and hematomas (arrows), curling of secondary lamellae and fusing of primarily lamellae and heavy proliferation of gill filament with the appearance of heavy numbers of spores and unseptated hyphae (**Photo 7**).

3.5.2. Histopathological Findings of the Infected *C. Carpio*

The Histopathological examination of the infected site of gills of *C. carpio* (**Plate 4**) showing severe hyperplasia in the epithelial lining the secondary lamellae, degenerative changes, necrosis and edema as well as the blood capillaries became large cysts (Arrows) (**Photo 8**), and complete destruction and proliferation in the epithelium of gill filament, dilation and congestion of blood vessels in primary lamellae, hyperplasia and swelling of secondary lamella, thickening of primary lamellae, proliferation in the epithelium of gill filaments and shortening of secondary lamellae , necrotic changes in secondary lamella, curling & edema (Arrows) (**Photo 9**). Such gill filaments contained necrotic residues with residues of congestion and some remains of fungal sporonts.

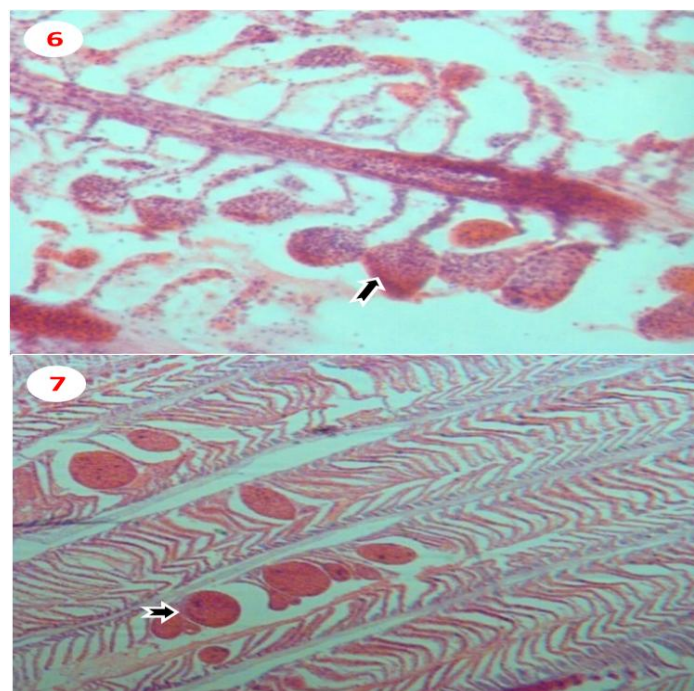


Plate3: Gills of *O. niloticus* showing dilation and congestion of blood vessels of primary lamellar epithelium, aneurism, swelling of secondary lamellae as well as Telangiectasis (arrows) (60X, H& E) (**Photo 6**) and hematomas (arrows) and curling of secondary lamellae (40X, H&E) (**Photo 7**).

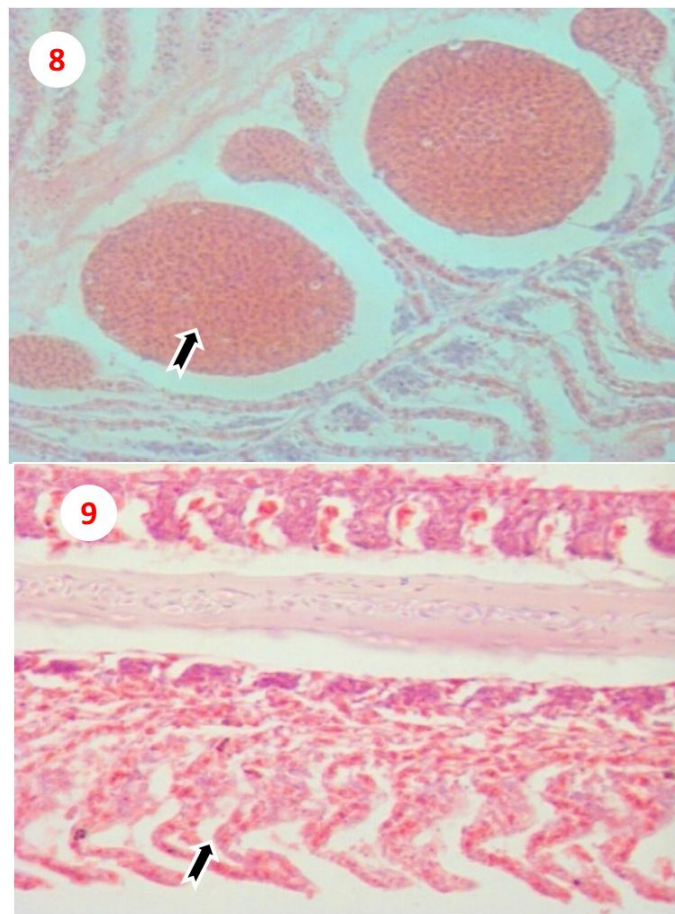


Plate4: Gills of *C. carpio* showing severe hyperplasia in the epithelial lining the secondary lamellae, degenerative changes, necrosis and edema as well as the blood capillaries became large cysts (Arrows), (H&E stain)(X 250) (**Photo 8**), and complete destruction and proliferation in the epithelium of gill filament (Arrows), dilation and congestion of blood vessels in primary lamellae, hyperplasia and swelling of secondary lamella, thickening of primary lamellae, proliferation in the epithelium of gill filaments and shortening of secondary lamellae, necrotic changes in secondary lamella, curling & edema (Arrows) (60 X, H&E) (**Photo 9**).

4. DISCUSSION

Branchiomycosis is an acute infection of the gills that can cause high mortality and respiratory distress in many species of ornamental and freshwater fish such as the Koi, the eel, the bass and the perch. It has been reported primarily in Europe and Taiwan but also in the southeast USA. The two most commonly isolated species are *Branchiomyces sanguinis* and *Br. demigrans* which have different host specificities and distributions (Noga, 2010).

The present study showed that the infected fish had respiratory distress including rapid movement of operculum and gasping of the fish on the surface of the water and these signs are similar to those mentioned by Neish and Elughes (1980); Klinger and Francis-Floyd (1996); Durborow et al. (2003) & Judy (2008), and gills appear striated or marbled with the pale areas which is a pathognomic lesions and this result is in agreement with those reported by Johnson (2008)& Ibrahim (2011).

These fungi affect only the gills, leading to localized gill damage, therefore called gill rot which causes acute signs of respiratory disorder and high mortality, due to anoxia and these result are similar to those reported by Klinger and Francis-Floyd (1996) & Paperna and Smirnova (1997). This may be attributed to the spores and hyphae of fungi infect; blood vessels of gill, gill arches and base of the primary lamellae cause an infarctive necrosis of gill that cause blockage and thrombosis, therefore termed "gangrenous branchitis," and these in agreement with Snieszko (1974); Chien et al. (1978); Ramaiah (2006); Saint-Erne (2008) & Ibrahim (2011).

Branchiomyces Demigrans Infection in Farm-Reared Common Carp (*Cyprinus Carpio L.*) and Nile Tilapia (*Oreochromis Niloticus*) at Different Localities in Egypt, With Special Emphasis to the Role of Environmental Stress Factors

This study also represented that Sabouraud's dextrose agar containing cyclohexamide, chloramphenicol, gentamycin, yeast extract, and agar is selective media for isolation of the *Branchiomyces* spp. from infected fish samples and this result agrees with **Post (1987) & El-Bouhy and Mahboub (2014)**.

Hyphal diameters of our isolates *Branchiomyces* spp. are ranging from 12 to 20 μm and spores diameters are ranging from 5 to 7 μm . These measurements of fungi are in agreement with those given by **Chien et al. (1978) & Svobodová and Vykusová, (1991)** which is assigned to *Br. demigrans*.

In contrary to our results, **El-Bouhy and Mahboub (2014)** mentioned that El-Behera governorate represented the highest prevalence of *Br. demigrans* in naturally infected *O. niloticus*.

The histopathology of the effected fish's gills shows the fusion of primary lamellae and the heavy proliferation of gill filaments with numerous numbers of spores and non-septated hyphae. These hyphae contain; multinucleated sporangium-like body, divided sporonts which could be uninucleated or binucleate bodies in various stage (sporonts). The localized cellular damage of the epithelial layer and the necrotic residues of congestion remain of some fungal sporonts and these results are in agreement with **Paperna and Smirnova (1997) & El-Bouhy and Mahboub (2014)**.

Bad environmental conditions constitute a major stress factors for induction of Branchiomycosis in naturally infected fishes. The outbreak of the disease occur due to environmental factor like hightemperature of the summer, and the bad-management such as transported and bad handling of entering new fish from other pond, which contributed into acceleration a favorable environment for the proliferation of this fungus and this in agreement with **Post (1987) & Paperna (1996)**. In Mycotic affections we should recognize a multiplicity of factors and should include appropriate quality control measures for water quality parameters (temperature, dissolved oxygen, nitrogenous wastes, etc.) as well as bacterial and other contaminants that may confound bioassay results and their interpretation (**Ali, 2005**).

REFERENCES

- [1]. **Ali, E. H., 2005**. Morphological and biochemical alternations of Oomycetes fish pathogen *Saprolegnia parasitica* as affected by salinity, ascorbic acid and their synergistic action. *Mycopathologia*, 159(2), 231-43.
- [2]. **Amlacher, E., 1970**. Textbook of fish diseases, T.E.S. Publication, New Jersey. USA, P. 117-135.
- [3]. **Austin, B., Austin, D. A., 1987**. Bacterial Fish Pathogens: Diseases in Farmed and Wild fish. Ellis Harwood limited England, PP: 250-262.
- [4]. **Chalmers, G. A., 2003**. Infectious Diseases of Silver Carp, *Hypophthalmichthys molitrix* (Valenciennes, 1844). Goldon A Chalmers, DVMLethbridge, Alberta, pp: 56.
- [5]. **Chien, C. H., Miyazaki, T., Kubota, S. S., 1978**. The histopathology of Branchiomycosis of eel in Taiwan. *JCRR Fish. Ser.*, 34, 97-98.
- [6]. **Durborow, R. M., Wise, D. J., Terhune, J. S., 2003**. Saprolegniasis (Winter Fungus) and Branchiomycosis of Commercially Cultured Channel Catfish. USA. SRAC Pub. 470 The Iraqi Journal of Veterinary Medicine; 35 (1), 1 - 9.
- [7]. **El-Bouhy, Mahboub, H. Heba, 2014**. Branchiomycosis in Nile tilapia (*Oreochromis niloticus*) in Behiera Governorate with Trials for Treatment. *Zag. Vet. J.* (ISSN. 1110-1458) Vol. 42 No. 3 pp. Vol. 42 (No. 3): pp. 29-42.
- [8]. **Ellis, A. E., 1977**. The leucocytes of fish: a review. *J. Fish Biol.* 11, 453-491.
- [9]. **Finegold, S. M., Baron, E. J., 1986**. Bailey and Scoll's Dignostic Microbiology .The Cv. Mosby co., St. Louis.
- [10]. **Ibrahim, K. S., 2011**. Isolation and pathological study of Branchiomycosis from the commercial pond of common carp (*Cyprinus carpio*) fish, in Governorate of Duhok / Iraq. *The Iraqi Journal of Veterinary Medicine*; 35 (1), 1 - 9.
- [11]. **Johnson, E., 2008**. Branchiomyces in Koi. Abstract last access 03, September 2010.
- [12]. **Judy, S., 2008**. Comparative Pathology of Fishes. Leger Sea World, San Diego USA. Last access 20, October 2010.

- [13]. **Klinger, R. E., Francis-Floyd, R. 1996.** Fungal Diseases of Fish. University of Florida. Institute of Food and Agricultural Sciences. November, 2010.
- [14]. **Leanor, D., Carey, S., 1978.** Laboratory methods in Medical Mycology. Public Health service center for diseases control, Bureau of Laboratories, laboratory Training and consultation division, Atlanta, Georgia, USA, 30: 333.
- [15]. **Lightner, D., Redman, R. M., Mohny, L., Sinski, J., Priest, D., 1988.** A renal mycosis of adult hybrid red Tilapia (*Oreochromis mossambicus x O. hornorum*) caused by the imperfect fungus *Paecilomyces marquandii*. J. Fish Dis., 11, 437-440.
- [16]. **Lio-Po, G. D., Lim, L. H. S., 2002.** Infectious diseases of warm water fish in fresh water. In: Diseases and Disorders of Finfish in Cage Culture (Ed. by P. T. K. Woo, D. W. Bruno & L. H. S. Lim), pp. 231–281. CABI Publishing, Wallingford.
- [17]. **Neish, G. A., Elughes, G. C., 1980.** Fungal diseases of fishes. Book 6 in S. F. Snieszko and I. R. Axelrod, eds. Diseases of fishes. T. F. H. Publications, Neptune, N. J. pp: 159.
- [18]. **Noga, E. J., 1996.** Fish Disease, Diagnosis and treatment. Iowa State University Press, pp: 193, Blackburg, VA, 24601-, USA, US Department of Agriculture.
- [19]. **Noga, E. J., 2010.** Fish disease: Diagnosis and treatment"; 2nd Edition, published by Wiley-Blackwell, 1-536.
- [20]. **Paperna, I., 1996.** Parasites, infections and diseases of fish Africa, an update. CIFA Technical Paper No. 31. FAO Rome.
- [21]. **Paperna, I., Smirnova, M., 1997.** Branchiomyces-like infection in a cultured tilapia (*Oreochromis hybrid*, Cichlidae). Dis. Aquat. Org., (31), 233-238.
- [22]. **Plumb, J. A., Bowser, P.R., 1982.** A laboratory Manual of Microbial fish Diseases. Auburn Univ., Auburn, Alabama, pp: 77.
- [23]. **Post, G., 1987.** Revised and Expanded Textbook of fish health 1st ed. (T.F.H.) publication, Inc. U.S.A by T.F.H. pp: 288.
- [24]. **Ramaiah, N., 2006.** A review on fungal diseases of algae, marine fishes, shrimps and corals. Indian Journal of Marine Sciences 35, 380–387.
- [25]. **Refai, M. K., Abd El-alim, M. M., Afify, M. M. H., Youssef, H., Marzouk, M. S., 1987.** Studies on Aspergillomycosis in catfish (*Glorias lazera*), 36 Tagung der EuropaischenGesellschaft Fur veterinarpathologie am of, June 1987 in Salzburg.
- [26]. **Roberts, R. J., 2001.** The mycology of teleosts. In fish pathology, 3rd ed. (Ed. by Roberts, R. J.), pp. 332.
- [27]. **Saint-Erne, N., 2008.** Diseases of Koi (*Cyprinus carpio*). Abstract abstracted from Infectious and Parasitic Diseases of Koi International association for aquatic animal medicine conference proceeding.
- [28]. **Snieszko, S. F., 1974.** The effects of environmental stress on outbreaks of infectious diseases of fishes. Fish Biol. 6, 197-208.
- [29]. **Svobodova, Z., Lloyd, R., Machova, J., Vykusova, B., 1993.** Water quality and fish health. EIFAC Technical Paper.No. 54. Rome, FAO. 59 p.
- [30]. **Svobodová, Z., Vykusová, B., 1991.** Diagnostics, prevention and therapy of fish diseases and intoxications. Research Institute of Fish Culture and Hydrobiology Vodňany Czechoslovakia: AP Písek. 80-90.
- [31]. **Yanong, R. P. E., 2003.** Necropsy techniques for fish. In Practical Gross Necropsy of Exotic Animal Species. Seminars in Avian and Exotic Pet Medicine., Echols S., ed. W.B. Saunders Co., Philadelphia, PA, pp: 89-105. Last access 11, September 2010.

AUTHORS' BIOGRAPHY



Riad H. Khalil is a senior professor of Fish diseases, Department of Poultry and Fish diseases, Faculty of Veterinary medicine in Alexandria University. He has over 15 years working experience fish microbiologist and research focusing on fish diseases and water resource management. He has contributed more than 75 articles in local and international scientific journals and has supervised 45 PhD and 85 master students



Talaat T. Saad is associate professor of Fish diseases, Department of Poultry and Fish diseases, Faculty of Veterinary medicine in Alexandria University. He has published more than 60 papers in reputed journals.



Talal A. M. Abo selema is a PhD student. He had finished his master thesis at 2012, specialized in Fish diseases, from Department of Poultry and Fish diseases, Faculty of Veterinary medicine in Alexandria University. His PhD mainly focused on a fungal disease affecting freshwater fish, namely Branchiomycosis.



Hany M. R. Abdel-Latif has completed his PhD at the age of 28 years from Alexandria University and postdoctoral studies from Michigan State University School of Veterinary Medicine. He is a Senior Lecturer of Fish diseases, Department of Poultry and Fish diseases, Faculty of Veterinary medicine in Alexandria University. He has published more than 11 papers in reputed journals