

Detection and Classification of Diabetic Retinopathy Condition in Retinal Images

CH. Shruthi

M-Tech Student, Dept. of ECE
G. Narayanamma Institute of Technology and Science
Hyderabad, INDIA
shruthi.chunchu@gmail.com

N. Ramakrishna

Asst. Professor, Dept. of ETM,
G. Narayanamma Institute of Technology and
Science, Hyderabad, INDIA
ramakn@gmail.com

Dr. N. Moorthy Muthukrishnan

Professor, Dept. of ETM
G. Narayanamma Institute of Technology and
Science, Hyderabad, INDIA
nmoorthy2001@yahoo.com

Abstract: *Human eye is very sensitive organ. Many important eye diseases as well as systemic diseases manifest themselves in the retina of the eye and retinal image analysis is very intricate task. Automated retinal image analysis for disease detection is very important for early diagnosis of eye diseases like diabetic retinopathy (DR). DR is a condition where the retina is damaged due to fluid leaking from the blood vessels into the retina in the diabetic patients. In extreme cases, the patient would lose his vision completely. Hence, early detection of diabetic retinopathy condition is very crucial to prevent blindness. This paper aims at developing an algorithm for early detection of DR condition and classification of retinal images. This paper includes extraction of abnormalities like Exudates from retinal images using K-means clustering and Top-Hat and Bottom-Hat operations, also classifying a retinal image as healthy or abnormal using K-NN classifier.*

Keywords: *Diabetic Retinopathy, K-means clustering, Top-Hat and Bottom-Hat operations, K-NN classifier*

1. INTRODUCTION

Several studies have indicated that many important eye diseases [1] as well as systemic diseases manifest themselves in the retina of the eye. The retina gets affected by long-term dietetic mellitus called Diabetic Retinopathy (DR). Diabetic retinopathy is a disease that affects individuals suffering from diabetes, and causes changes to the blood vessels found within the retina, resulting in decreased vision and blindness. The retina is light sensitive layer at the back of the eye that senses light and transmits images to the brain. Reports of Vision 2020[2] states that, this disease is a significant cause of vision loss. World-wide out of diabetic patients who have had the disease for more than 15 years, 2% become blind and another 10% develop severe vision impairment.

Often occurring without noticeable symptoms, DR damages the blood vessels of the retina in four stages namely, Mild Non-Proliferative retinopathy, Moderate Non-Proliferative retinopathy, Severe Non-proliferative retinopathy and Proliferative retinopathy. Mild Non-proliferative retinopathy is earliest stage among four stages, and at this stage occurs, the Exudates which are bright yellow-white deposits on the retina. As the disease progresses, it enters next stage, Moderate Non-proliferative retinopathy. Here some of the blood vessels that nourish the retina get blocked. In severe stage, many more blood vessels get blocked, depriving blood supply to several parts of retina. These parts of retina send signals to the body to grow new blood vessels so as to provide critical nourishment for the retina. Proliferative retinopathy is the advanced stage, where lack of oxygen causes fragile blood vessels to grow along the retina and also within the vitreous gel that fills the eye. Lack of timely treatment causes, these new blood vessels bleed, blur the vision, and damage the retina. At any stage, there is a chance for fluid leakage into the center of the macula (part of the retina responsible for sharp, straight-ahead vision). This fluid causes

macula to bulge and blur the vision. This condition is called macular edema. About half of people with proliferative retinopathy also develop macular edema.

Therefore, timely treatment reduces the chance of the vision loss in diabetic patients [2].

The figure below shows the vision of healthy person versus vision of person affected with Diabetic Retinopathy.




Fig1(a). Vision of a healthy person **(b)** Vision of a person with advanced diabetic retinopathy.

Exudates are one of the primary signs of diabetic retinopathy [3]. Exudates are bright yellow-white deposits and they appear on the retina due to the leakage of blood from abnormal vessels. The shape and size of exudates will vary with different retinopathy stages. Detection of these exudates by ophthalmologists requires pupil dilation using a chemical solution, which will be risky, takes time and affects patients.

Hence, this paper aims at developing an algorithm for automatic detection of exudates and also classification of a retinal image as healthy or abnormal. The objective of this algorithm is to facilitate the diagnosis of diabetic retinopathy in general screening programs.

2. GENERAL ARCHITECTURE

The general architecture of the proposed method is shown in the following block diagram.

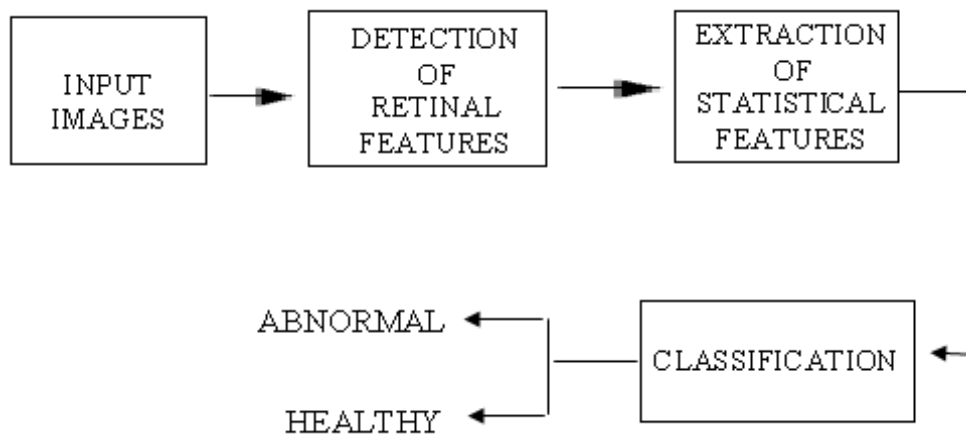


Fig2. General Architecture

The input retinal images are read from an image database [4] and retinal features (exudates) are detected using segmentation methods [5]. Statistical features (mean standard deviation and principal components [6]) from the retinal feature detected image are extracted and used as training data-sets to a classifier. The classifier system [7] [8] classifies the image as healthy or abnormal, by comparing the statistical features of new image with the trained data-set.

2.1. Proposed Method

The Algorithm for implementing the proposed method is organized in to two phases namely,

1. Training Phase and
2. Verification Phase.

2.1.1. Training Phase

Training phase constructs an image-space, which is used to train a classifier system. Later, this image space is required for classification in verification phase.

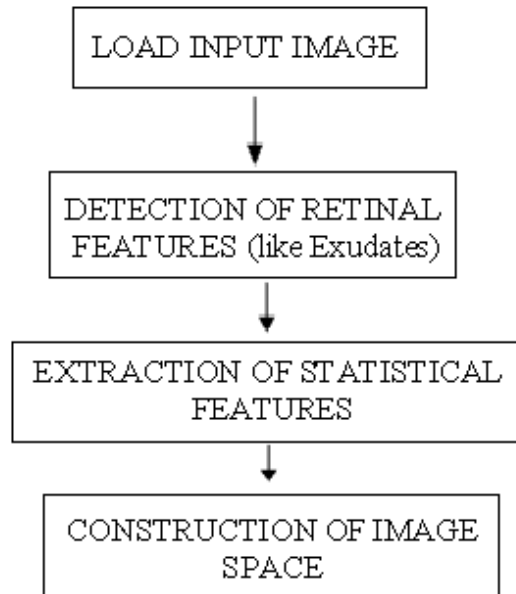


Fig3. Flowchart explaining procedure implemented in training phase.

- a) Load a retinal image from the retinal image data base.
- b) Detection of Retinal Features

Retinal features are detected using two different methods in this paper:

- (i) Using Top-Hat and Bottom-Hat operations and
- (ii) Using K-means clustering.

Top-Hat and Bottom-Hat Operations Based Detection

Step1: Read the retinal image as input and resize it to 512×512 pixels.

Step2: Extract the green component of the image.

The green channel of the retinal image is used for efficient segmentation, since it has the highest contrast between the blood vessels and the retinal background and it shows a good variation between the optic disk and the background.

Step3: Morphological Bottom-Hat (BH) operation is performed.

Firstly, green component image is closed by structure element with a radius of 11 pixels. The operation is as follows:

$$f \bullet B = (f \oplus B) \ominus (B) \quad (1)$$

Where f is the original image (green component image), B is the structure element, symbol (\bullet) is the gray-scale morphological closing operation, symbol (\oplus) is the gray-scale dilation and symbol (\ominus) is the gray-scale erosion operation. Now, the original image (green component image) is subtracted from the resultant image of equation (1). This operation is known as morphological Bottom-Hat operation given by Eq. (2).

$$BH = (f \bullet B) - f \quad (2)$$

By this operation the low grey level components such as vessels are extracted. This step is developed in order to improve the exudates detection accuracy. Since during the exudates

extraction step, the candidate regions are only preliminary, several false positive may appear in image such as vessel artefacts. So with the mask that is obtained in this step, these artefacts can be eliminated.

Step4: Morphological Top-Hat (TH) operation is performed.

Bright components such as exudates pened. The original green component image is subtracted from the morphologically are obtained using this step. In Top-Hat operation, green component image is morphologically oopened image. Hence areas of higher intensities can be localized. This operation is given by Eq. (3):

$$TH = (f \circ B) - f \tag{3}$$

Where symbol (\circ) is the gray-scale morphological opening operation given by Eq. (4):

$$f \circ B = (f \ominus B) \oplus (B) \tag{4}$$

For structure element B , a disk shape is used. Here in addition to bright components, vessels are seen.

Step5: Subtract resultant image of step 4 from the resultant image of step 3.

That is, in order to extract exudates precisely, the resultant image of Top-Hat operation is subtracted from resultant image of Bottom-Hat operation.

K-Means Clustering Based Detection

K-Means Clustering [9] is an iterative algorithm which is used to partition an image into K clusters. The basic steps for this algorithm are:

- (a) Define K cluster centers for an image.
- (b) Assign each pixel of the image to a particular cluster, that has minimum distance between the pixel and the cluster center.
- (c) Re-compute the cluster centers by averaging all the pixels in the cluster
- (d) Repeat steps (b) and (c) until convergence is attained (no pixels change clusters)

In this case, difference is considered to be absolute difference between pixel and cluster center. This difference is generally based on pixel color, intensity of pixel, location or weighted combination of these factors. Value of K can be selected randomly or by any heuristic. The quality of the solution depends on the initial set of clusters and the value of K.

In this paper, K is considered as 5, there by 5 clustered images are formed. The image, which partitions retinal features accurately, is considered for extracting statistical features.

c) Extraction of Statistical Features

To feed the classifier, the information to use for classification, mathematical measurements (features) of the image are required [10]. In this paper, three different statistical features (mean, standard deviation and principle components) are extracted from the resultant images of section (i) and (ii).

Mean: Mean is average gray-scale value (which is the first moment of the texture).It is calculated using the formula,

$$mean \mu = (1/N) \sum X_i \tag{5}$$

Where i =Number of pixels from 1 to N .

X_i = Individual pixel value.

N = (Total no of number of pixels)

Standard deviation (SD): It is average contrast (the standard deviation σ , is the square root of the second moment). Standard deviation is calculated using the formula,

$$SD = \sigma = \sqrt{\frac{1}{N} \sum_{i=0}^N (X_i - \mu)^2} \tag{6}$$

Where i = Number of pixels from 1 to N

N = Total no of pixels

μ = mean

X_i = Individual pixel value.

PCA based extraction of Principal components (Eigen vectors): Principal Component Analysis (PCA) identifies relatively fewer “features” or components that as a whole represent the full object state which are appropriately termed “Principal Components”. Principle components (Eigen vectors) are calculated from the resultant images of section (i) and (ii) using PCA algorithm as follows.

Step1: Read each sample image X , feature extracted image from section (i) or (ii), and convert it into a row vector.

Step2: Calculate the mean vector μ of sample image.

$$\mu = (1/n) \sum X_i, \text{ where } n = \text{no of elements in row vector.}$$

Step3: Subtract mean μ from original image and create a new intermediate matrix IM .

$$IM = X - \mu$$

Step4: Find the data covariance matrix C of that intermediate matrix IM .

$$C = IM^t * IM, \text{ where } IM^t \text{ is transpose of } IM.$$

Step5: Find the Eigen values from covariance matrix. Pick ten highest valued Eigen values which are termed as “principal components”.

Repeat the procedure for all the images of dataset and pick the principal components of each image.

d) Construction of Image Space

In this paper, three different image spaces are constructed namely, image spaces of mean, standard deviation (SD) and principal components. Image spaces of mean and SD are, individual row vectors of mean values and SD values of resultant images of section (B). Image space of principal components is a matrix constructed using Eigen vectors. These are used as reference for classification in verification phase.

2.1.2. Verification Phase

In verification phase, retinal features of each new image from retinal image dataset are extracted and its statistical features (principal components, mean and standard deviation) are extracted. These statistical features are compared with those features in the image-space with the help of a classifier.

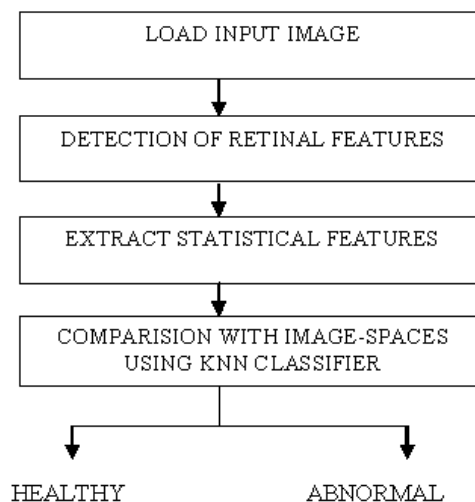


Fig4. Flowchart explaining procedure implemented in verification phase.

In this phase, load a new image from the retinal image database and detect the exudates similar to section (B) in training phase.

Principal components, mean and standard deviation are extracted from the retinal feature detected images similar to section (C) of the training phase.

Comparison using K-NN classifier

These extracted statistical features are fed to a K-NN classifier [11] where the new image is classified as Healthy or Abnormal.

2.2. K-NN Classifier

K-NN stands for “K-Nearest Neighbour algorithm”. It is one of the simple and widely used machine learning algorithms. Here, an object is classified by the “distance” from its neighbours, with the object being assigned to the class which is most common among its k distance-nearest neighbours (K is a positive integer, typically small). If K = 1, then the object is simply assigned to the class of that single nearest neighbour. In this paper, K=1 is considered for classification of retinal image. The advantage of using K-NN classifier is, it’s easy to implement.

3. RESULTS AND DISCUSSIONS

The proposed method is verified on 30 retinal images (15 normal images and 15 abnormal images) from High Resolution Fundus (HRF) image database and 5 abnormal images collected from an eye hospital in Hyderabad, India.

The intermediate simulation results of exudates detection using Top-Hat and Bottom-Hat operations:

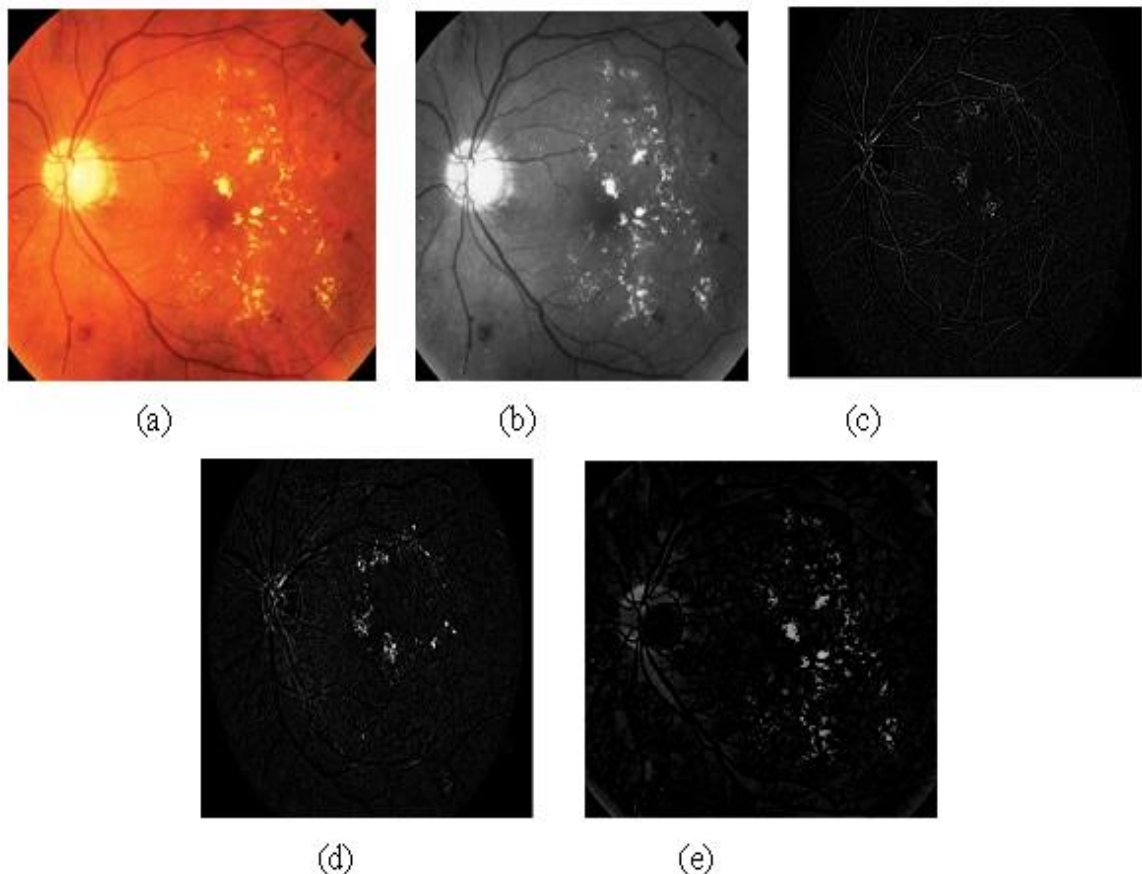


Fig5(a). Input Image (b) Green Component Image (c) Morphological Bottom-Hat operated image (d) Morphological Top-Hat operated image (e) precisely extracted exudates.

In the above figure 5(a) is the original colour retinal image taken from the database. 5(b) is the extracted green component of image 5(a), where good contrast between background and retinal artefacts is found, 5(c) is the image after applying morphological Bottom-hat operation to green component image, where blood vessels of retina are highlighted. 5(d) is the image after applying morphological Top-hat operation to green component image, where exudates are highlighted.

Finally, 5(e) is the resultant image obtained after subtracting 5(d) from 5(c). In this final image exudates are visible precisely.

The intermediate simulation results of exudates detection using K-means clustering:

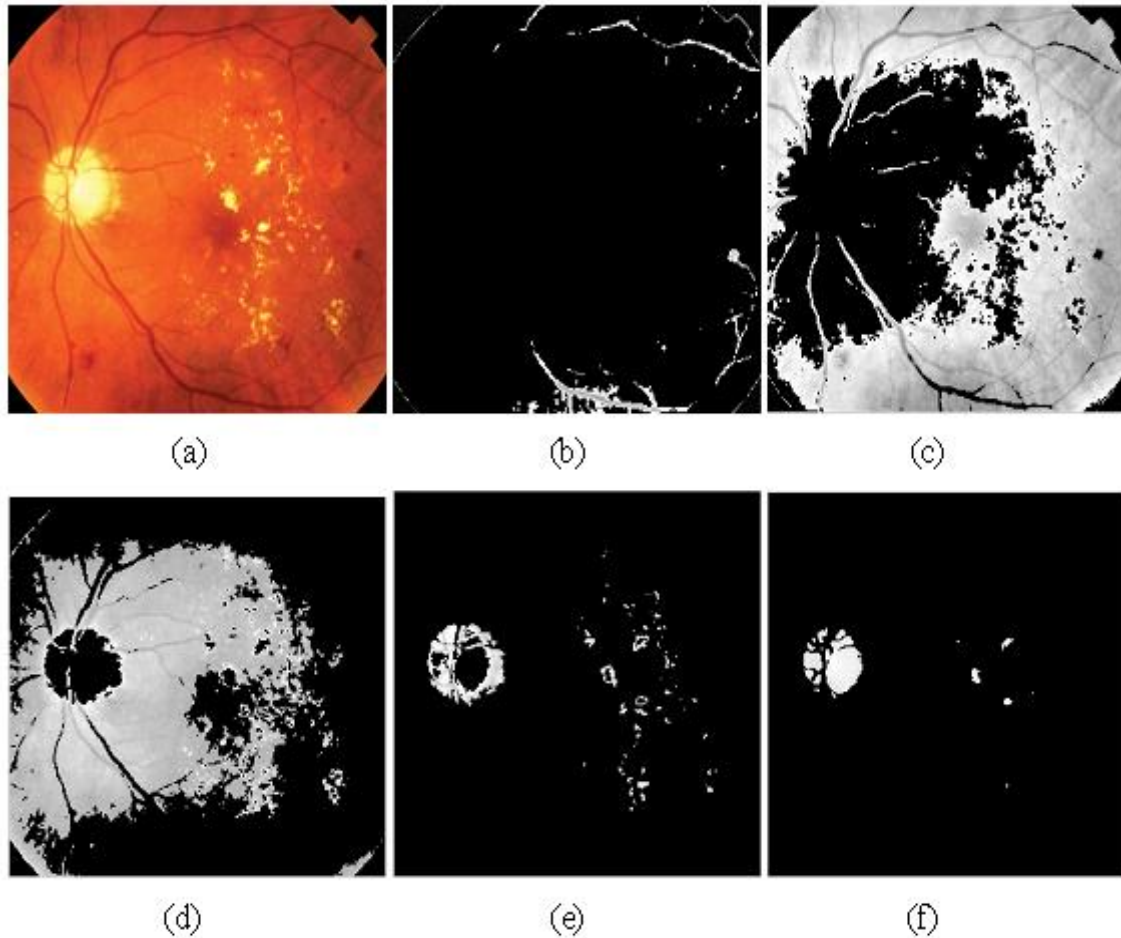


Fig6(a) input image (b) cluster-1 image (c) cluster-2 image (d) cluster-3 image (e) cluster-4 image (f) cluster-5 image

In the above figure 6(a) is the original color retinal image. 6(b), 6(c), 6(d), 6(e), 6(f) are the images of first to fifth clusters respectively. Abnormalities (exudates) are precisely visible in cluster 4 and 5 along with OD (optical disc).

3.1. Graphs Showing Variation Between Statistical Features Extracted Using Top-Hat and Bottom-Hat Operations

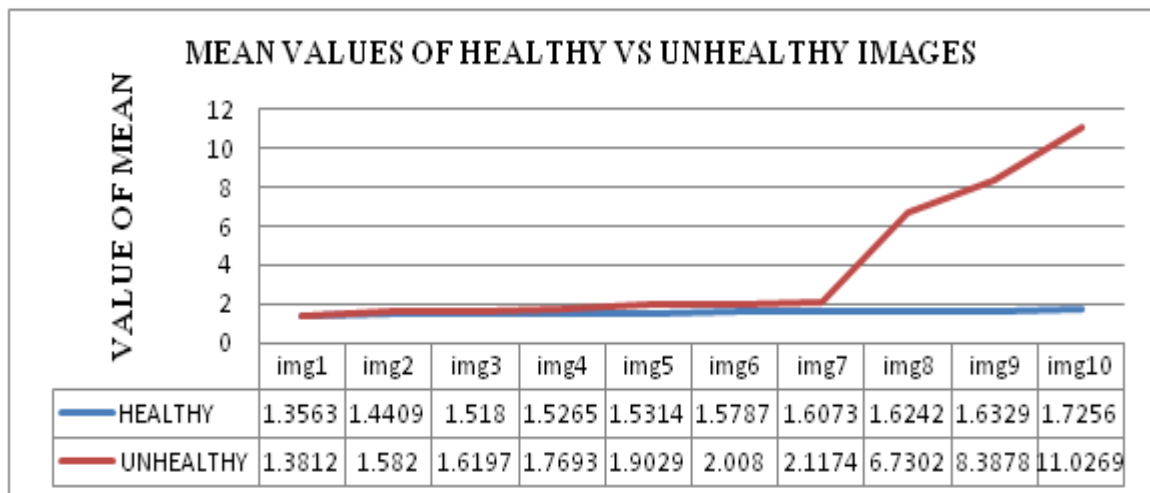


Fig7. Mean values of healthy vs abnormal images

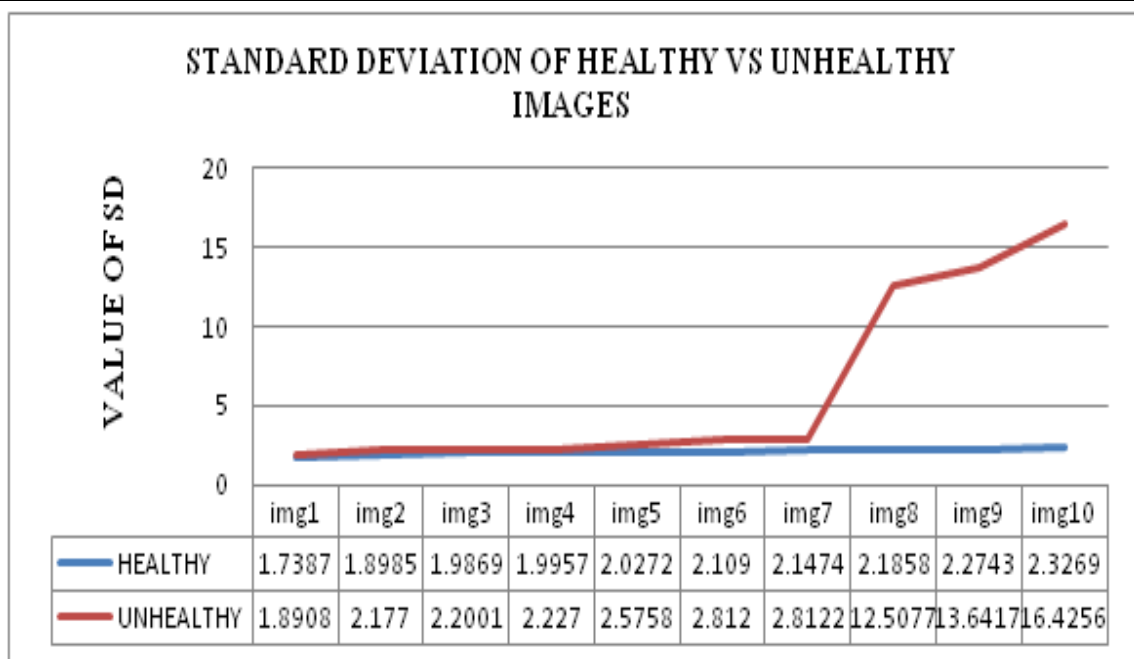


Fig8. Standard deviation(SD) values of healthy vs abnormal images

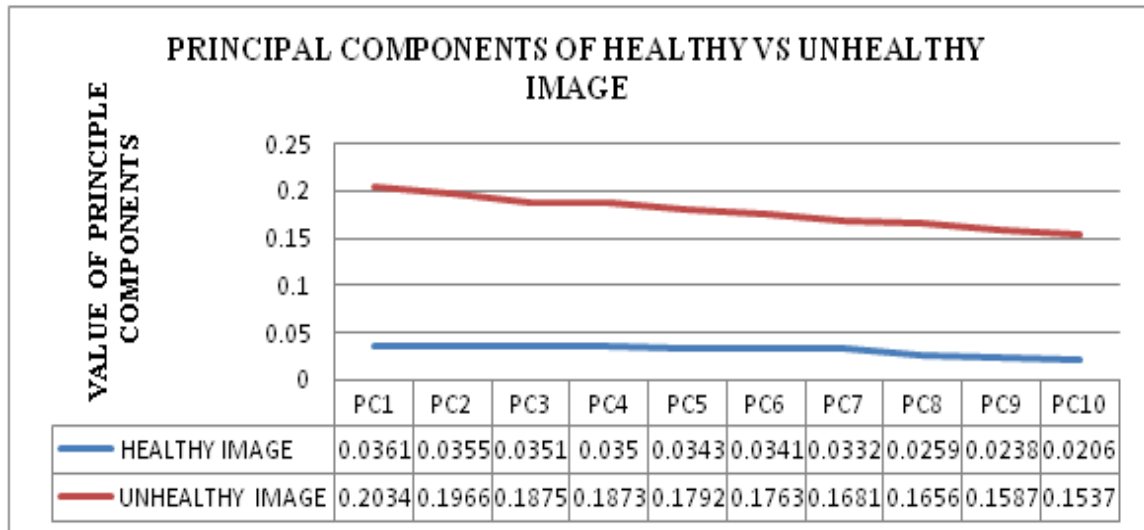


Fig9. Top ten Principal Component (PC) values of healthy vs abnormal image

3.2. Graphs Showing Variation Between Statistical Features Extracted Using K-Means Clustering

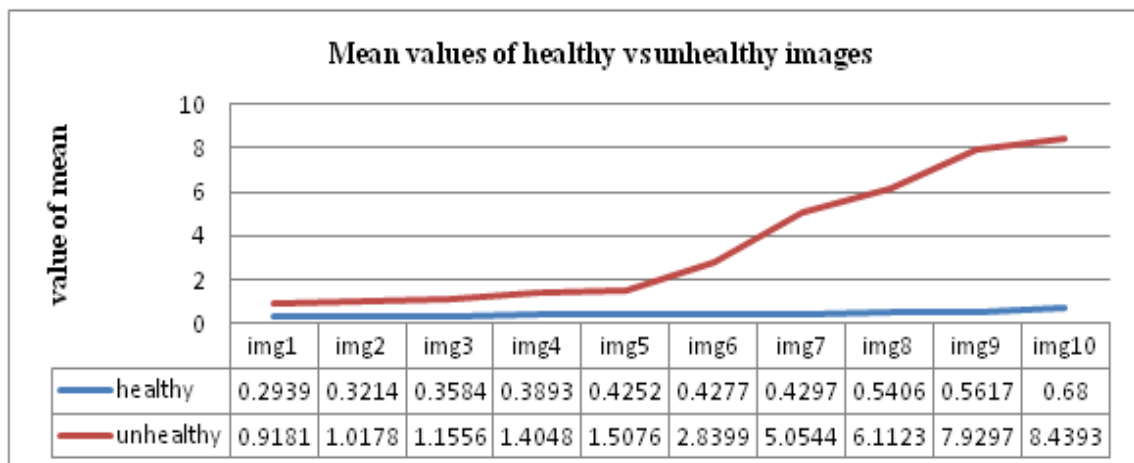


Fig10. Mean values of healthy vs abnormal images

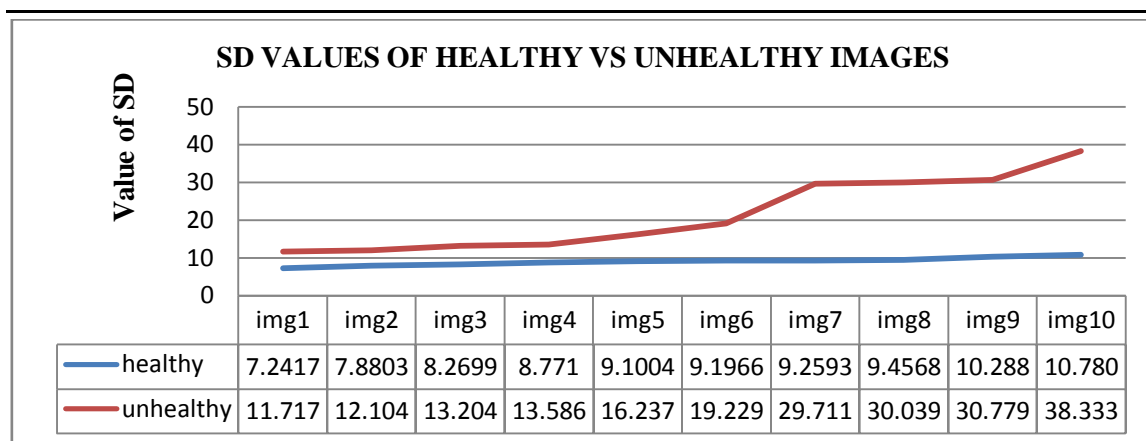


Fig11. Standard deviation (SD) values of healthy vs abnormal images

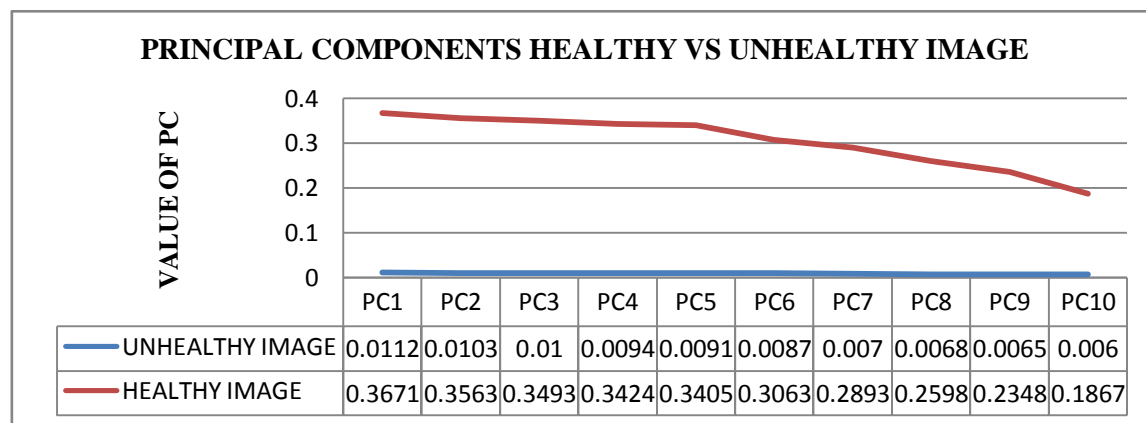


Fig12. Top ten Principal Component (PC) values of healthy vs abnormal image

These graphs indicate the “variation” between the values of three different statistical parameters, which is the base for a K-NN classifier system to find out nearest neighbour for a new image. This variation is found better for the statistical parameters extracted by using K-means clustering compared to Top-hat and Bottom-hat operations. Hence, a K-NN classifier system classifies a retinal image as healthy or abnormal.

4. CONCLUSION

Diabetic Retinopathy (DR) is a chronic disease of the ocular retina, which is often discovered when the disease is on an advanced stage and most of the damage is irreversible. For that reason, early diagnosis is paramount for avoiding the most severe consequences of the DR, of which complete blindness is not uncommon.

This paper proposed an algorithm to implement, an automated system to identify early signs of DR from Retinal images. Retinal features are detected using two simple techniques namely, Top-Hat and Bottom-Hat operations based method and K-means clustering. Statistical parameters like mean, standard deviation and also principle components from resultant images of these two retinal feature detection methods are calculated. And K-NN classifier system is used for classification of a retinal image as Healthy or Abnormal based on these statistical parameters.

Hence, this paper proposed a simple and efficient algorithm to implement an automated system for detection and classification of DR condition in retinal images. The proposed method is verified on 15 healthy and 15 abnormal images of HRF database [4] and 5 abnormal images from an eye hospital. The proposed work could be used as diagnosis tool to detect abnormal retinas in mass screening programs.

REFERENCES

- [1] Kevin Noronhal and Prabhakar Nayak. K, have proposed, ” Fundus Image Analysis for the Detection of Diabetic Eye Diseases-A Review”, 2012 International Conference on

- Biomedical Engineering (ICoBE). Vision2020.org.WHO <http://www.vision2020.org/main.cfm?>
- [2] EmanM.Shahin,Taha.E, Al-Nuaimy.W, El Rabaie.S, Osama F.Zahran and Fathi E. Abd El-Samie," Automated Detection of Diabetic Retinopathy in Blurred Digital Fundus Images",IEEE transactions 2012.
- [3] High Resolution Fundus image (HRF) database <https://www5.cs.fau.de/research/data/fundus-images/>
- [4] Aqeel F AQEEL and Subra Ganesan," Retinal Image Segmentation using Texture,Thresholding and Morphological Operations", IEEE International Conference on Electro/Information Technology, May 15-17, 2011
- [5] Afshin Shaabany and Fatemeh Jamshidi,"Image classification Decreasing of Principal component Analysis" IEEE 2012.
- [6] Imran Sarwar Bajwa, Syed Irfan Hyder,"PCA based image classification of single layered cloud types"International Conference on Emerging Technologies IEEE 2005.
- [7] Vipin Krishnan C V ,V.S.Jayanthi and Jestin V Kunjummen," Iterative Kernel PCA based Classification of Retinal Images for Diabetic Macular Edema",International Journal of Computer Applications , 2013.
- [8] Vijay Jumb, MandarSohani, AvinashShrivastava,"Color Image Segmentation Using K-Means Clustering and Otsu's Adaptive Thresholding", International Journal of Innovative Technology and Exploring Engineering (IJITEE) ISSN: 2278-3075, Volume-3, Issue-9, February 2014
- [9] Syna Sreng, Noppadol Maneerat, Don Isarakorn, Jun-ichi Takada and Ronakorn Panjaphongse M.D." Feature Extraction from Retinal Fundus Image for Early Detection of Diabetic Retinopathy"IEEE 2013.
- [10] Suguna. N, Dr.Thanushkodi .K, "An Improved k-Nearest Neighbor Classification Using Genetic Algorithm", International Journal of Computer Science Issues, Vol. 7, Issue 4, No 2, July 2010