

Smile Tips in Patients with Normal Occlusion and Class II/1 Malocclusion

Irena Gavrilovic, DMD, MSc (Orthodontist)

Faculty of Dental Medicine, University "St Cyril and Methodious", Dental Clinical Center, Orthodontic Department, Vodnjanska 17 Skopje, Macedonia, i.gavrilovic@yahoo.com

Abstract

The lips and teeth are part of the person who draws our attention during the conversation. Since ancient times, women highlighted lips using various means for their coloring. And today lipstick is a major component in women's cosmetics. With aging lips become thinner and less defined, while in young individuals lips are more fuller and more round. The smile is a result of muscles activity. Some orthodontic malocclusions can be reason for changes in the smile and smile arch.

We determined the tip of the smile in male and female patients with normal occlusion and malocclusion Class II Division 1, and we find that the most represented smile is commissural smile (70%) in patients with normal occlusion, more in male (75%) than in female (67%) group. In patients with Class II/1 Malocclusion before treatment commissural smile was present with 60% and supra-commissural was present with 30%. After orthodontic treatment supra-commissural smile was present with 17% and commissural smile was present with 83%. Among the three studied groups we did not find the presence of infra-commissural smile.

Keywords: Smile, Tip Of The Smile, Class II Division 1 Malocclusion, Normal Occlusion.

1. INTRODUCTION

The face is the mirror of the people's soul. We say that a smile is a reflection of his character. People who are extrovert, communicative usually have a big smile which shows most of the teeth in the lateral region, and people whose are closed, introverted, rarely show teeth during the smiling.

The face of people attracts us or rejects us, disappoints or excites us. The face can be a gentle, mild, proudly, blank, hot, cold, sharp, joyous, sad.

There are different terms for a smile that is descriptive and subjective express inner feelings and personality, and also we describe the smile, such as impersonal, bitter, sarcastic, ironic, inexplicable, infectious, warm and enigmatic.

Lips are constructed from soft tissues, the muscles and glands. The outer part of the lip is covered with leather and the inner mucosa.

The upper border of the upper lip is actually the base of the nose, and the border with the cheeks is naso-labial sulcus. This ridge extends from the wings of the nose towards down and out and ends up in the corners of the lips. With aging these grooves are increasingly appointed.

The lower lip is bordering the chin with sulcus mentolabialis. Sulcus depth depends of the thickness of the lip, chin emphasis, bite depth and the age of the patient.

The connection between the upper and lower lip is in the corners of the mouth. Canines and their location between the frontal teeth and lateral segments have a major role in the aesthetics of the lips and hold the corner of the mouth not to collapse.

The position of the corners of the lips (commissures) also affects at the symmetry of smile, but there are no specific studies that show the connection between asymmetry and negative or buccal space. In some studies, the authors emphasize that despite wide smile exposes more posterior teeth, it is still a more pleasant, less than the smile that shows them less.

In recent years with the advancement of technology it is possible to devote more attention to the analysis of the smile. Designing the smile is multifactorial process whose success depends on the clinical possibility of soft tissue response to conducted orthodontic treatment.

Angle (1907) considers that the position of the lips is an important criterion for facial aesthetics.

The aesthetic smile is a result of the interaction of various components that form the smile, and we need to understand the principles which are involved in creating a balance between the teeth and soft tissues.

Bimler (1,2) have examined the factors that determine the harmony and disharmony of the face and came to the conclusion that the parts of the face are inherited as complex, but independent of each other. This leads to the creation of many different configurations of people.

Hulsey (3) indicates that the smile has the greatest influence through which people communicate their emotions. His trials were intended to answer two questions: Is the smile of orthodontic treated patients is as attractive as a smile at patients with normal occlusion? What is the position between the lips and teeth that the orthodontist should take care during the orthodontic treatment?

The response was as follows: - Orthodontic treated patients have significantly “poorer” smile compared to patients with normal occlusion and - in the most attractive smiles upper lip is leaning, (resting), at the height of the marginal gingiva of the maxillary central incisors. But we can say that at patients with orthodontic treatment, smile before treatment, have been significantly enhanced after orthodontic treatment.

The arch of the smile affects the aesthetics of the smile. The ideal smile arc is actually when the line described by the curvature of the incisal edges of maxillary incisors parallel to the curve of the lower lip. Hulsey (4) in his studies found that patients who were treated orthodontic comes to correcting the arc smile, which is considered less aesthetic than in untreated patients.

The position of the corners of the lips (commissures) also affects the symmetry of the smile, but so far there are no specific studies that show the connection between asymmetry and negative or buccal space. In some studies, the authors emphasize that despite wide smile exposes more posterior teeth, is still a more pleasant, less than the smile that shows them.

Tjan and Miller (5) defined the smile line into 3 groups: high smile line (gingival smile) which fully show the maxillary incisors and of the gingiva, average smile line where the incisors are seeing 75-100% and bottom line of a smile, when people looked incisors are less than 75%.

Peck, Peck and Kataja (6) came to the conclusion that the gingival smile is associated with greater anterior maxillary height and ability of muscle elevators to the upper lip raised, significantly more in raising the average lip smile. Found that other variables were significantly associated with gingival smile as increased o.j., increased inter-labial space at rest and increased o.b.; while factors that are not associated with gingival smile is length of the upper lip, the length of the clinical crown of the incisors, the angle of mandibular plane and the angle of palatinalplane. But with aging comes to reducing the visibility of maxillary incisors and increases the visibility of mandibular.

1.1. Purpose

Considering from the fact that the smile has a major role in the completion of facial aesthetics, there is a need that every orthodontist during correction of the malocclusions is participating in improving of the smile. Evaluation of the smile in patients with Class II Division1 Malocclusion, before and after orthodontic treatment, we assessed through the following tests:

- To determine which type of smile is represented;
- Is there a gender differentiation in terms of a certain kind of smile

2. MATERIAL AND METHOD

To realize this goal, we investigated 60 patients, 30 of them were patients with Class II Division 1 Malocclusion and made digital photographic images before and after orthodontic treatment.

Smile Types in Patients with Normal Occlusion and Class II/1 Malocclusion.

As a control group we made digital images of 30 patients with normal occlusion, showing dental relations of Class I and have a harmonious face and smile.

Some measurements were made using a small cephalometric orthodontic ruler. The other part of the measurements was made on previously captured photographic images.

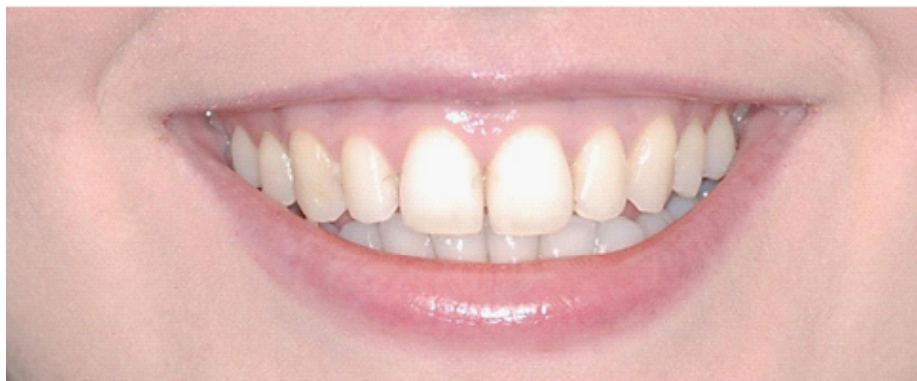All patients were between 15 to 18 years of age, with permanent dentition.

Therapy in patients with Class II Division 1 malocclusion, took 1.5 year to 2 years and 2 months, followed by a period of retention with mobile orthodontic appliances.

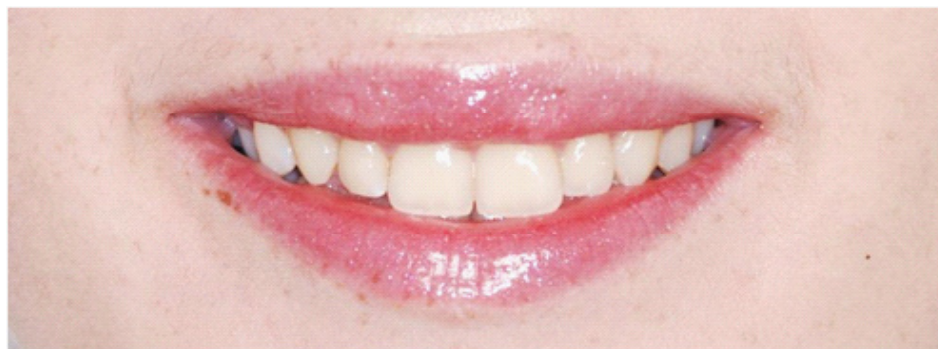The following measurements were made:

Type of the smile - we draw a line passing between the commissures of the mouth serves as a reference line on the basis of which received 3 types of dentolabial smile:

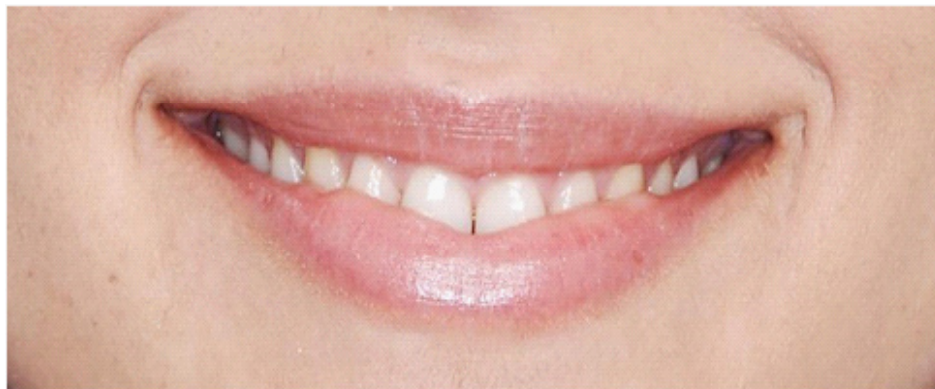- **Supra-commissural** - when the base of the free edge of the upper lip is above intercomisural incisal line or edge of the maxillary incisors follow the curvature of the lower lip.



- **Commissural** - when the base of the free edge of the upper lip matches intercomisural line



- **Infracommissural** - when the base of the free edge of the upper lip is under comisural line



3. RESULTS AND DISCUSSION

Table1. Percentage representation of the kind of smile in the group with normal occlusion

No of patients	Commissural		Supra-commissural		Infra-commissural	
12 male Normal occlusion	9	75%	3	25%	0	0%
18 female Normal occlusion	12	67%	6	33%	0	0%
30 (all)	21	70%	9	30%	0	0%

The table shows that in the group with normal occlusion commissural smile is dominant (70%), more in men (75%) compared to women (67%). Supra-commissural smile is represented with 30% (33% among women and 25% of the male group). Infra-commissural line is not represented at patients.

Table2. Percentage representation of the kind of smile in the group with Class II/1 Malocclusion before treatment

No of patients	Commissural		Supra-commissural		Infra-commissural	
15 male	8	53%	7	47%	0	0%
15 female	10	67%	5	33%	0	0%
30 (all)	18	60%	12	40%	0	0%

Table 2 shows that commissural smile is represented by 60% in patients with Class II/1 before treatment, 67% of female patients and 53% of male patients. Supra-commissural smile is represented with 40%, 47% of men studied group and 33% of women studied group. And there are no patients with infra-commissural smile.

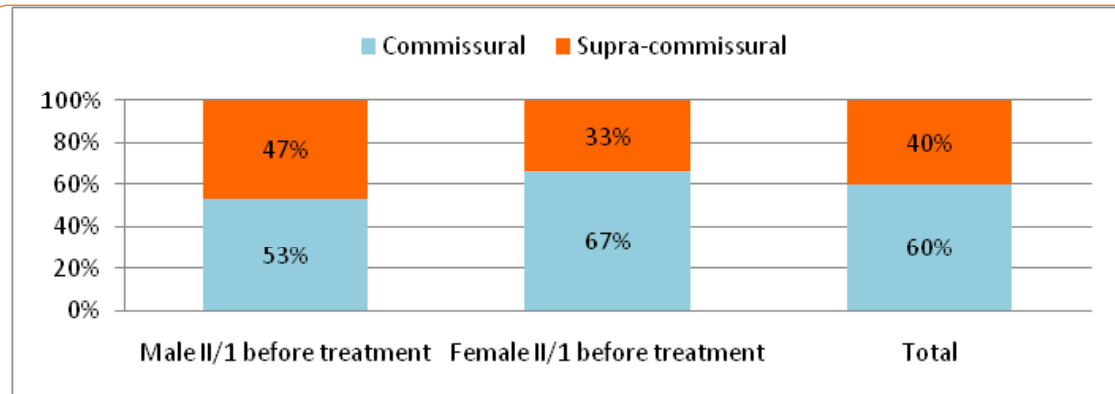


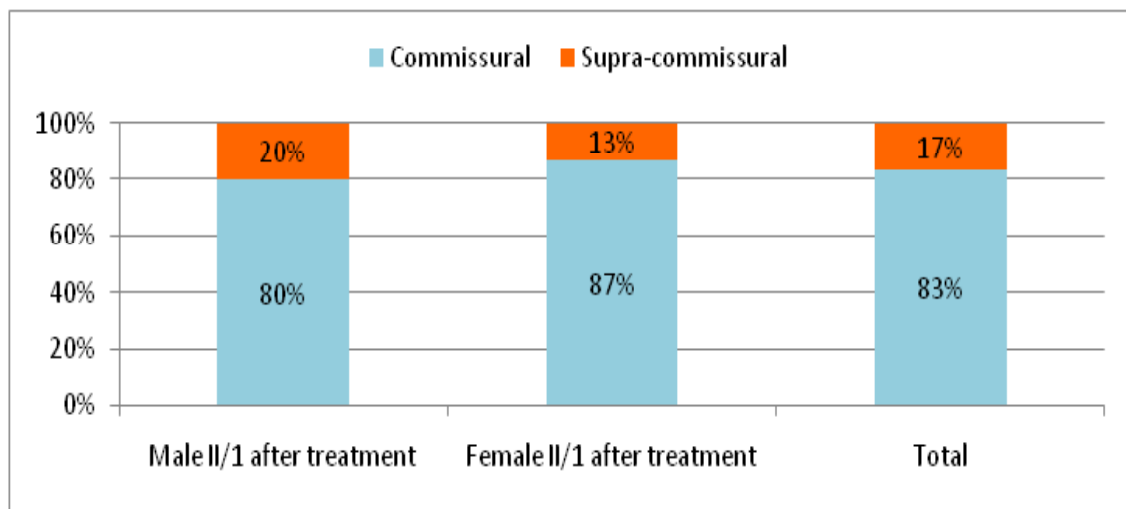
Chart1. Percentage representation of the kind of smile in the group with Class II/1 before therapy

Table3. Percentage representation of the kind of smile in the group with Class II/1 Malocclusion after treatment

No of patients	Commissural		Supra-commissural		Infra-commissural	
15 male	12	80%	3	20%	0	0%
15 female	13	87%	2	13%	0	0%
30 (f+m)	25	83%	5	17%	0	0%

Table 3 shows that after treatment the number of patients with commissural smile is 83%, 87% are of the women patients and 80% of the men patients. Commissural smile is represented with 17% (13% in the female group and 20% in the male group). And there are no patients with infra-commissural smile.

Chart2. Percentage representation of the kind of smile in the group with Class II Division 1 Malloclusion after treatment



Before we start the treatment, during a conversation with patients we should observe what type of muscle activity occurs. Are lips touching each other when are in a relaxed position? Is there too much movement of the tongue? Are the upper lips moves while smiling? Are the teeth exposed only when smiling or speaking? In all these trials may have noticed that some lips show greater mobility while others are less mobility.

Photographs taken during a smile should be involved in determining the diagnosis and treatment plan. When we take frontal and lateral photographs with lips at rest position or lips are touching one another, we analyze from the static point of view, while in photography with a smile we analyze the nature characteristics of patients in dynamic position of the lips.

Interestingly to mention that for the formation of the smile the perioral muscle activity has a major role in moving and pulling the corners of the lips. In a study done by Haruna Okamotoa and all (7) in 155 adult female patients, the full-face photographs at maximum contraction of the corner of his lips, the smile portrait at rest, come to the conclusion that the left angle of mouth has significantly higher displacement than the right, the group had symmetry in portrait smile.

The smile arc is determined by the curve that describes the maxillary incisors and canines with respect to the line of the lower lip Shyam Desay (8):

- Parallel - when incisal edge of maxillary incisors follow the curvature of the lower lip
- Flat - when incisal edge of maxillary incisors is without a curvature and is flat.
- Invert - when incisal edge of maxillary incisors is inversely positioned relative to the curvature of the lower lip.

In our study we separate the smile as commissural, supra and infra-commissural. We made this separation in relation to the next - we draw a line passing between the commissures of the mouth, which serves as a reference line on the basis of which received 3 types of dento-labial smile:

Our findings coincide with the findings of Shyuam Desai (8) found that the most typical is commissural smile or correct arch smile. We found that commissural smile is represented with 70 % in normal occlusion group, 60 % in group II/1 prior therapy and 83 % in group II/1 after therapy. This coincides with the findings obtained by Tjan and al, Yoon and al and Owens and all (8), which give values of 84.8 %, 60 % and 74 %.

Supra-commissural smile is represented with 30 % in the group with normal occlusion, 40 % of group II/1 before treatment and 17 % in the group with Class II/1 Malocclusion after treatment.

4. CONCLUSION

Orthodontists must know that aesthetic principles governing facial and dental harmony can be achieved with optimal tooth position within the soft tissue and skeletal characteristics of each patient.

We came to the following conclusions:

- Among the three studied groups we did not find the presence of infra-commissural smile. In the group with normal occlusion commissural smile is dominant (70%) and more in males group (75%) compared with female group (67%), while supra-commissural smile is represented with 30% (33% in females and 25% males patients). In group with Class II Division 1 Malocclusion before treatment commissural smile prevails 60% more in female group (67%) compared to male (53%). Supra-commissural smile is represented with 40%, with a higher proportion of representation in males (47%) compared to females (33 %). After therapy increases the percentage of commissural smile (83%) and more in females (87%) compared to males (80%). Supra-commissural smile is present only 17%, more in male group (20%), compared to the female (13 %).

In conclusion based on the results, we can say that optimal smile is characterized when the upper lip touches the gingival edge of the maxillary incisors with commissural smile upper incisal line coincides with the border of the lower lip, with minimal or no buccal space, and harmony between dental and gingival components.

REFERENCES

- [1]. Beckman S. H., Kuitert R. B., B. Prah-Andersen, D. Segner, B.Tuinzing ,Alveolar and skeletal dimensions associated with overbite, Am J OrthodDentofacialOrthop, 134: 443-52, 1998.
- [2]. Beckman S. H., Kuitert R. B., B. Prah-Andersen, D. Segner, B.Tuinzing,Alveolar and skeletal dimensions associated with lower face height - Am JOrthodDentofacialOrthop, 113: 498-506,1998.
- [3]. Mackley R. J., An evaluation of smiles before and after orthodontic treatment,The Angle Orthodontists, Vol 63, No 3, 1993.
- [4]. Parekh Manhar Sanjay, D.D.S. , The Perception of selected aspects of smile esthetics, Smile arch and Buccal Corridors,Degree of Master of Science in the Graduate School of The Ohio State University,Pp 23-26,2005.
- [5]. Geron Silvia, Wasserstein Atalia ,Influence of Sex on the Perception of Oral and Smile Esthetics with Different Gingival Display and Incisal Plane Inclination, Angle Orthodontist, Vol 75, No 5, 2005.
- [6]. Peck S. DDS, MscD, Peck L. DMD MSD, Kataja M PhD, The gingival smile line, Angle Orthodontist, Vol. 62, No 2, 1992.
- [7]. Okamoto Haruna and all, Laterality of Asymmetry in Movements of the Corners of the Mouth during Voluntary Smile, Angle Orthodontist, Vol 80, No 2, 2010.
- [8]. Desai Shyam G. B.S.D.M.D., Dynamic Smile Analysis: Changes with Age, Master thesis University of Connecticut, Health Center, Pp 37-38, 2008.

AUTHOR BIOGRAPHY



Dr Irena Gavrilovic is Specialist of Orthodontic and Master of Science (Chances in lip position of patients with Class II Division 1 Malocclusion). She is a teaching assistant at Faculty of Dental Medicine, University "St Cyril and Methodius", Dental Clinical Center, Orthodontic Department in Skopje and Vice presidents of Macedonian Orthodontic society. Her fields of interests are treatments of Class II/1, Class II/2 and Class III Malocclusion with removable and fixed orthodontic appliances.

Citation: Irena Gavrilovic (2015) Smile Types in Patients with Normal Occlusion and Class II/1 Malocclusion. IJHSSE 2(3), pp: 75-80.