

Radiculitis and its Current Approach

Dr. Avinash Shankar^{1*}, Dr. Amresh Shankar², Dr. Anuradha Shankar³

¹MD (Internal Medicine), DNB(E&M); PhD, Postgraduate in Endocrinology & Metabolism (AIIMS-Delhi), Chairman, Institute of Applied Medicine, National Institute of Health & Research, Warisaliganj (Nawada) Bihar, 805130

²BAMS (BRABU); MHA, Hon Director, Aarogyam Punarjeevan, Ram Bhawan, Ara Garden, Jagdeopah, Baily Road, Patna 14

³BAMS (BRABU), Ex Director, Centre For Indigenous Medicine & Research, Senior Research Fellow cum Medical Officer, Regional Institute of Ayurveda Research, Itanagar (Arunachal)

***Corresponding Author:** Dr. Avinash Shankar, MD (Internal Medicine), DNB(E&M); PhD, Postgraduate in Endocrinology & Metabolism (AIIMS-Delhi), Chairman, Institute of Applied Medicine, National Institute of Health & Research, Warisaliganj (Nawada) Bihar, 805130

Abstract: Radiculitis, an agonizing painful condition is due to inflammation of the spinal nerve root or roots in the region of neural foramen and its presentation is termed as Radiculopathy which commonly affect the cervical and lumbar region

Incidence of lumbar radiculopathy is 5% to more than 30% with a lifetime prevalence of 60% to 90% and cervical radiculopathy is 107.3 per 100,000 for men and 63.5 per 100,000 for women with a peak at 50 to 54 years of age.

In spite of advancement in diagnostics i.e- CT scan and MRI and treatment with traction, surgical decompression and other adjuvant like neuro vitamin supplementation and analgesic antiarthritic supplementation satisfactory clinical response with improved quality of life remain a challenge, thus a therapeutic regime combined with herbal neurotonic and neuro vigorantive been evaluated in patients who failed to respond the present therapeutics

Objective of study

To assess the herbal neurogenic containing therapeutic regime ensuring clinical relief and improving quality of life in patients of radiculopathy

Material & Method

718 diagnosed and already treated cases of radiculopathy attending at Centre for Critical Care, National Institute of Health & Research Warisaliganj (Nawada) Bihar been selected, interrogated, examined clinically, assessed and analysed their previous investigation reports, therapeutics taken and their effect.

Irrespective of their clinical severity all patients were advocated the prescribed regime and were followed for post therapy 2 years for which patients been given a follow up card to record the changes.

Result

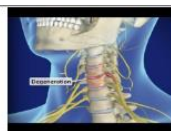Patients of mild, moderate and severe grade of clinical presentation shows grade I clinical response with improved quality of life in 100%, 80.2% and 88.4% patients respectively, though 0.9% and 1.9% of moderate and severe grade of clinical severity fails to prove worth.

No patients of either status had alteration in bio parameters or any adversity during therapy or 2 years of post-therapy follow up.

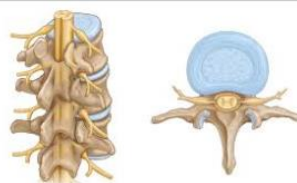Keywords: Radiculitis, Radiculopathy, cervical, lumbar, CT, MRI, herbal neurogenic, neurovigorantive, quality of life

1. INTRODUCTION

Radiculitis synonym of radicular pain i.e.- alteration in sensation or muscle power produced due to inflammation of spinal nerve root Or roots in the region of neural foramen and its presentation is termed as Radiculopathy Or Pinched nerve with common presentation as – Pain, weakness, numbness or difficulty in controlling specific muscles¹. On basis of its common area of involvement i.e.- cervical and lumbar region it is also known as Cervical and lumbar Radiculitis or radiculopathy



(Cervical radiculopathy)



(Lumbar radiculopathy)

The incidence of low back pain is estimated to be 5% to more than 30% with a lifetime prevalence of 60% to 90%. Approximately 50% of cases will resolve within one to two weeks. 90% of cases will resolve in six to 12 weeks. The incidence of radicular symptoms in patients presenting with low back pain ranges from 12% to 40%. While an annual incidence of cervical radiculopathy of 107.3 per 100,000 for men and 63.5 per 100,000 for women with a peak at 50 to 54 years of age. ^(2,3)

It is mechanical compression of nerve root usually at the exit foramen or lateral recess secondary to degenerative disc disease, osteoarthritis, facet degeneration or hypertrophy, ligamentous hypertrophy, spondylolisthesis or its combination though rarely also caused by radiation, diabetes mellitus, neoplastic disease Or any meningeal disease ^(4,5,6)

Common presentation	Preceding factors
Agonising pain in the back	Accidental injury
Pain during walking	Heavy weight lifting
Pain during changing posture	Recurrent fever & debility
Pain in neck	Diabetes mellitus
Tingling numbness in the extremity	Post parturition in female

As per American College of Radiology projectional radiography is an appropriate tool for initial study, Magnetic resonance imaging (MRI) of the portion of the spine. Electrodiagnostic testing, consisting of NCS (nerve conduction study) and EMG (electromyography), are more significant and specific diagnostic tool to ascertain nerve root injury. Needle EMG is considered most sensitive tool to reveal active denervation in the distribution of the involved nerve root, and neurogenic-appearing voluntary motor units in more chronic radiculopathies (7,8,9)

Present therapeutics i.e.- traction, cervical collar or abdominal belt, transdermal steroid injection, epidural injection, analgesics, calcium supplementation, vitamin D3 supplementation, fails to ensure cure in all the cases thus a therapeutic regime containing herbal neuro rejuvenator been evaluated for its clinical efficacy and safety profile. (10,11,12,13,14)

Objective of the study

Ascertain clinical efficacy and safety profile of herbal neuro rejuvenator containing regime in patients of radiculitis non responsive to existing therapeutics.

Duration of study

January 2014 to December 2016 with 2 years rigorous follow up from January 2017-December 2018 for post therapy symptom withdrawal or any drug adversity.

2. MATERIAL & METHODS

Material

Patients of radiculopathy treated and non responsive to present therapeutics attending Centre For Critical Care National Institute Of Health & Research

Warisaliganj were selected for evaluation of the present therapeutic regime clinical efficacy and safety profile.

Methods:

Selected patients and their attendants were thoroughly interrogated for onset of disease, clinical presentation, therapeutics taken and their response, any untoward effect or exacerbation of clinical presentation, preceding factors, clinically examined (Sparling's test for Cervical radiculitis and Straight leg raising test (SLR) for lumbar radiculitis. In addition, deep tendon reflex (Stretch reflex) was also elucidated. ^(15,16)

Kuchla	1gm
Jatamanshi	1gm
Chitrak	1gm
Mashkalayee	1gm
Shunthi	4gm
Amarlata	0.5gm
Ashvagandha	1gm
Kuth	1 gm

Patients were evaluated for duration required for relief in clinical presentation and to adjudge safety profile bio parameters were repeated every 3 months and at the end of therapy . In addition each patients were give a follow up card to enter the date of relief of presentation and nay untoward effects

Based on the clinical improvement therapeutic efficacy was graded as

Clinical grade	Characteristics
Grade I	Complete absence of presenting feature in 6 months of therapy without any untoward effects, drug adversity or withdrawal
Grade II	Complete absence of presenting symptoms and sign needing > 1 yr of therapy without any untoward effects, adversity or withdrawal
Grade III	Only symptomatic relief with withdrawal presentation

3. OBSERVATION

Selected patients were of age group 15-above >50 yrs out of them 2.22% were of 15-20 years while 27.8% were of age >50 years (Table-1)) and 434(60.4%) were male and 284(39.6%) female (Figure 1) Out of all 5.4% (39) were suffering since <1year while 23.8%(171) were since >5 years (Figure -2); 76(10.6%),212 (29.5 %) and 430(59.9%) were of mild ,moderate and severe degree presentation respectively (Figure -3). 404 (210 male and 194 female) were suffering with lumbar radiculitis and 314 (224 male and 90 female)with cervical radiculitis (Figure -4); 94.7%(680) were non vegetarian and 5.3%(38)were pure vegetarian (Figure -5);204(28.4 %) were with <IBW and 318 (44.3 %) with >IBW (Figure-6)

Clinical improvement was observed by 4th week in 4 patients of mild, while by 6th week in 6 and 97 patients of moderate and severe grade of severity. all patients of mild grade by 14th week while 210 and 420 patients of moderate and severe grade by 20th week of therapy (Figure -7)

All of mild grade severity achieved grade I clinical recovery while only 170 and 380 of moderate and severe grade of clinical severity respectively (figure -8). All cases of either mild moderate and severe grade of clinical severity had radiological improvement except 02 and 08 cases of moderate and severe grade remain unchanged. No patients of either status had any change in bioparameters during therapy and 2 years of post-therapy follow up. (Table- 2)

In short observation can be summarized as-

RADICULOPATHY

(718)

Cervical Radiculopathy		Lumbar Radiculopathy
314		404
Mild	Moderate	Severe
76	212	430
All by 14 th week	99% by 20 th week	97.4 % by 20 th week
Started in 4 th week	6 th week	6 th week
Grade I -76	170	380
Grade II – 0	40	42
Grade III- 0	02	08

4. DISCUSSION

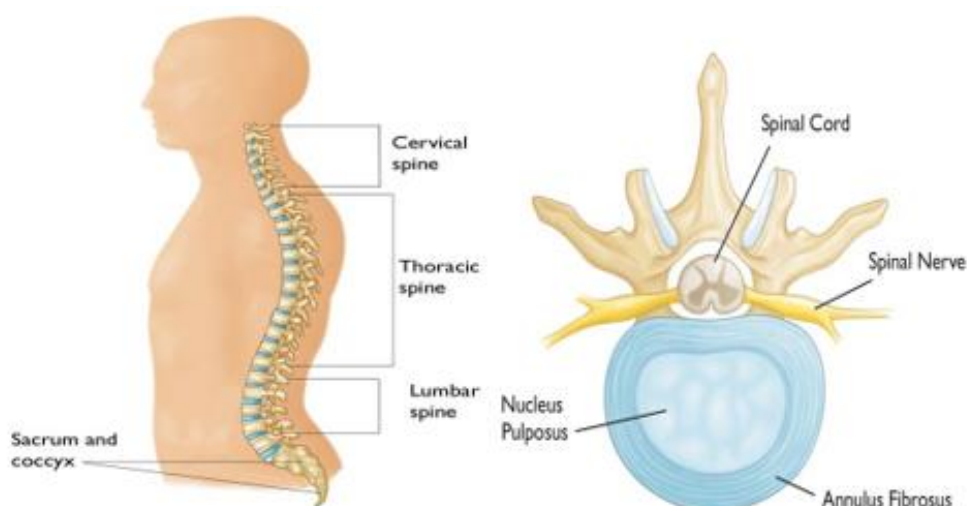
Radiculitis, an agonising painful condition due to pinching of spinal nerve root at the exit or in vertebral spine is increasing these days may be due to emergence of non nutrient in diet changing life style predisposing for cholecalciferol compromise resulting in degenerative process.

Our spine constitutes 24 bones termed as vertebrae and are stacked one over other and connect to create a canal to protect the spinal cord

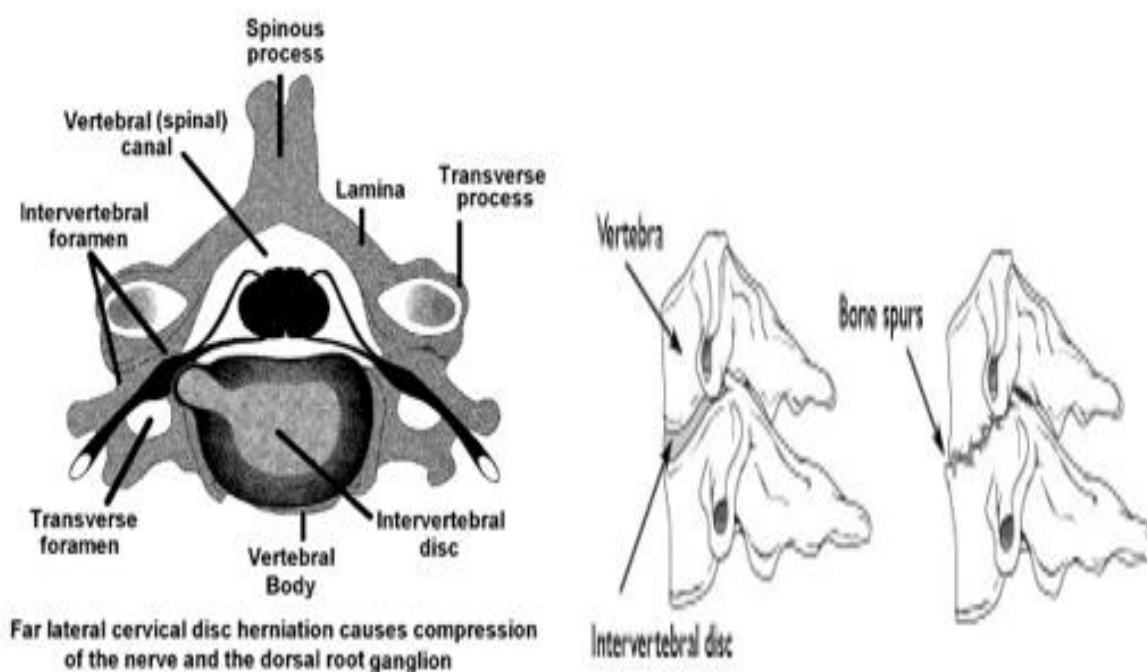
Spinal cord and nerves, an "electrical cables" travel through the spinal canal carrying messages between brain and muscles. Nerve roots branch came out from the spinal cord through openings in the vertebrae (foramen).

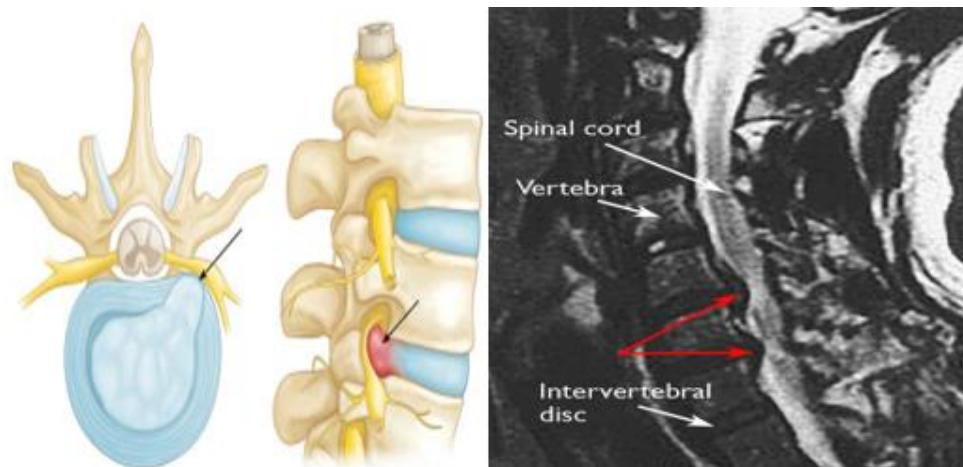
In between the vertebrae are flexible intervertebral discs which act as shock absorbers during movement or walking or running Intervertebral disks are flat, round, about 1.25 cm thick and are made up of two components:

- Annulus fibrosus. This is the tough, flexible outer ring of the disk.
- Nucleus pulposus. This is the soft, jelly-like center of the disk.



Thus any change in the intervertebral disc or adjacent bony part of vertebrae will compress the emerging nerve and cause inflammation of nerve resulting in agonizing pain full condition, also termed as Radiculopathy, which can affect cervical, thoracic and lumbar vertebral spine but out of them commonest are cervical and lumbar radiculopathy





The commonest investigation to confirm the lesion are X-ray ,CT and MRI of the vertebral column .

The common conventional treatment only ensure transient pain relief and 718 cases of all ready treated cases with persistent agonising state of mild, moderate and severe grade of clinical presentation shows grade I clinical response with improved quality of life in 100%,80.2% and 88.4% patients respectively ,though 0.9% and 1.9% of moderate and severe grade of clinical severity fails to prove worth .

No patients of either status had alteration in bio parameters or any adversity during therapy or 2 years of post therapy follow up .

This clinical achievement of the present therapeutic regime can be explained as¹⁷⁻

Betamethasone acting as anti inflammatory reduces neural edema synergized by Intravenous Calcium administration whose inclusion of one mole exit 2 mole of Sodium acting on Sodium potassium ATPase pump and facilitate decrease in neural edema and calcium ion improves neural conduction .

In addition supplementation of Calcium and cholecalciferol ensure baone repair by oestogenesis and check degenerative changes .

Methyl cobalamine , pyridoxine ,Niacin and pantothenic acid support neural cells in its normal neural conduction and Neurovit a herbal composite by its neurogenic activity helps in restoration of neural viability and vitality which combinely ensure relief in pain ,neuropathic manifestation , Oral aceclofenac with muscle relaxant relieve agonizing pain while transdermal absorption of active constituent of Myoneurol oil helps ensure sustained pain relief .

Exercise facilitates mobility at the particular vertebral joints and sooth painful agony .

Thus bioregulatedosteogenesis and neural function by reducing neural edema and repairing joint facets , ensure sustained therapeutic out come and improved quality of life .

5. CONCLUSION

Present therapeutic regime constituting intravenous Calcium gluconate, Methylcobalamine, pyridoxine, niacin and D panthenol with Betamethasone 2mg intravenous,Cholecalciferol ,Herbal neuragen and transdermal neurotropic local application with active and passive exercise proves worth in management of Radiculopathy .

TABLES & LEGENDS

Table1. number of patients

Age group In years	Number of patients			Percent
	Male	Female	Total	
15-20	10	06	16	2.22
20-25	20	12	32	
25-30	30	18	48	
30-35	32	14	56	
35-40	70	42	112	
40-45	68	40	108	
45-50	88	58	146	
>50	116	84	200	27.8
	434(60.4)	284(39.6)		

Pie diagram showing male:female composition

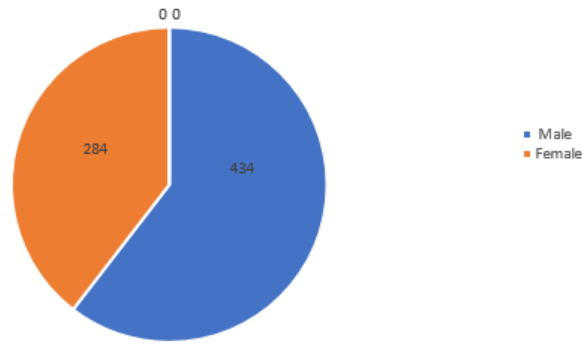


Figure1. Pie diagram showing male: female composition

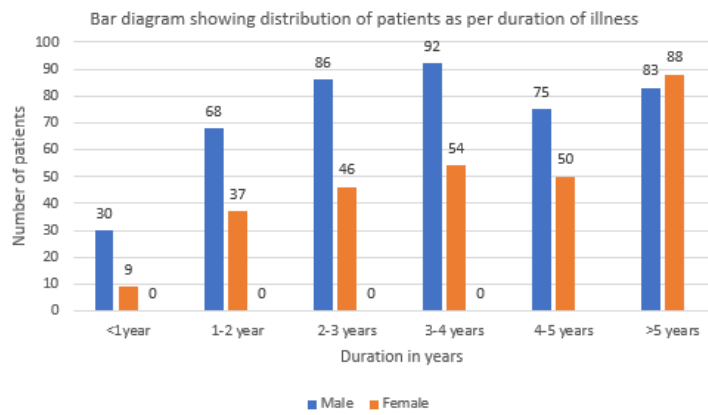


Figure2. Bar diagram showing distribution of patients as per duration of illness

Pie diagram showing distribution of patient as per severity of illness

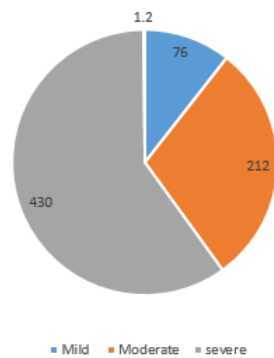


Figure3. Pie diagram showing distribution of patient as per disease stat

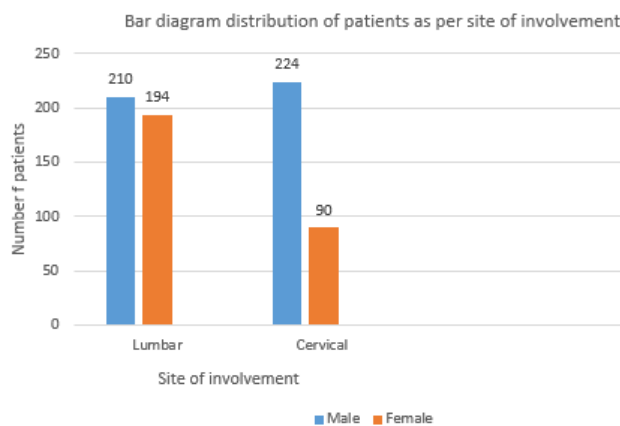


Figure4. Bar diagram showing distribution of patients as per area of involvement

Pie diagram showing dietary status

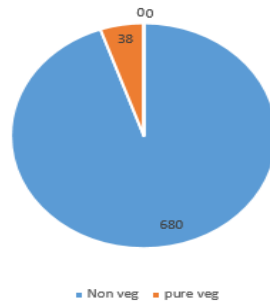


Figure5. Pie diagram showing dietary status

Bar diagram showing distribution of patient as per body weight

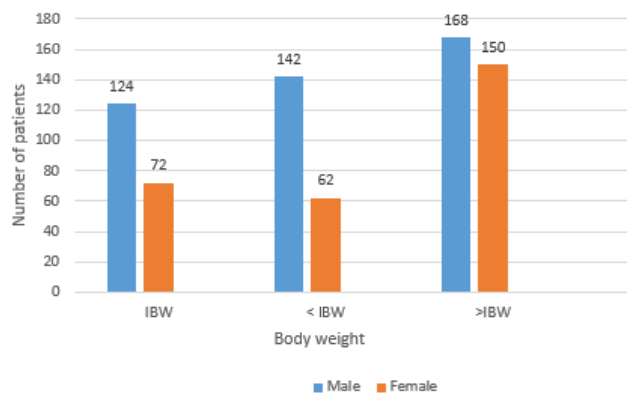


Figure6. Distribution of patients as per body weight

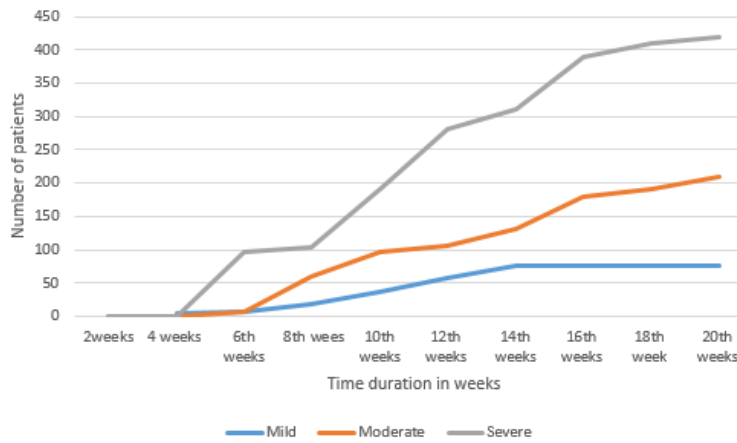


Figure7. Graph showing duration of treatment for relief of presentation

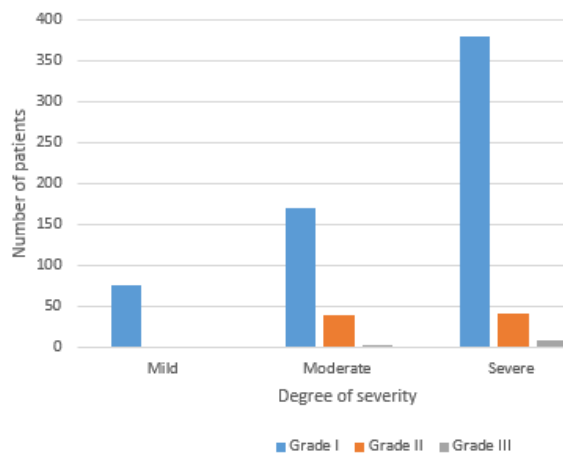


Figure8. Clinical grade of out come

Table2. Showing out come of the study

Particulars Clinical severity →	Number of patients		
	Mild	Moderate	Severe
Complete relief of presentation	76	210	422
Withdrawal presentation : :	-	2	8
Radiological status :			
Improved :	76	210	422
Un altered :	-	2	8
Worsen:	-	-	-
Post therapy bio parameters			
Hepatic profile:			
SGOT			
<35IU	76	212	430
SGPT			
<35IU	76	212	430
Alkaline phosphatase			
<100	76	212	430
Renal parameters:			
Blood urea			
<26mg%	76	212	430
Serum creatinine			
<1.5mg%	76	212	430
Urine:			
Albumin –Negative	76	212	430
RBC-Negative	76	212	430
Haematological :			
Haemoglobin			
>10gm%	76	212	430
Clinical grade:			
Grade I	76	170	380
Grade II	-	40	42
Grade III	-	02	08

REFERENCES

- [1] M. J. HubenyRadiculitis Published Online:May 1 1933 <https://doi.org/10.1148/20.5.331>
- [2] Hoy D, Brooks P, Blyth F, Buchbinder R. The Epidemiology of low back pain. *Best Pract Res ClinRheumatol.* 2010 Dec;24(6):769-81. [PubMed]
- [3] Radhakrishnan K, Litchy WJ, O'Fallon WM, Kurland LT. Epidemiology of cervical radiculopathy: a population-based study from Rochester, Minnesota, 1976 through 1990. *Brain.* 1994;117(Pt 2):325–335. [PubMed] [Google Scholar]
- [4] Tarulli AW, Raynor EM. Lumbosacral radiculopathy. *NeuroClin.* 2007 May;25(2):387-405. [PubMed]
- [5] Kennedy DJ, Noh MY. The role of core stabilization in lumbosacral radiculopathy. *Phys Med RehabilClin N Am.* 2011 Feb;22(1):91-103. [PubMed]
- [6] Urits I, Burshtein A, Sharma M, Testa L, Gold PA, Orhurhu V, Viswanath O, Jones MR, Sidransky MA, Spektor B, Kaye AD. Low Back Pain, a Comprehensive Review: Pathophysiology, Diagnosis, and Treatment. *Curr Pain Headache Rep.* 2019 Mar 11;23(3):23. [PubMed]
- [7] Nguyen HS, Doan N, Shabani S, Baisden J, Wolfla C, Paskoff G, Shender B, Stemper B. Upright magnetic resonance imaging of the lumbar spine: Back pain and radiculopathy. *J Craniovertebr Junction Spine.* 2016 Jan-Mar;7(1):31-7. [PMC free article] [PubMed]
- [8] Al Nezari NH, Schneiders AG, Hendrick PA. Neurological examination of the peripheral nervous system to diagnose lumbar spinal disc herniation with suspected radiculopathy: a systematic review and meta-analysis. *Spine J.* 2013 Jun;13(6):657-74. [PubMed]
- [9] Miyoshi K. [Dissociation of Anatomical (Neurological) Diagnosis and Imaging Diagnosis]. *Brain Nerve.* 2019 Mar;71(3):249-256. [PubMed]
- [10] Wenger HC, Cifu AS. Treatment of Low Back Pain. *JAMA.* 2017 Aug 22;318(8):743-744. [PubMed]
- [11] Ament JD, Karnati T, Kulubya E, Kim KD, Johnson JP. Treatment of cervical radiculopathy: A review of the evolution and economics. *SurgNeurol Int.* 2018;9:35. [PMC free article] [PubMed]
- [12] Lukies MW, Teoh WW, Clements W. Safety of CT-guided cervical nerve root corticosteroid injections. *J Med Imaging RadiatOncol.* 2019 Mar 12; [PubMed]
- [13] Mattozzi I. [Conservative treatment of cervical radiculopathy with 5% lidocaine medicated plaster]. *Minerva Med.* 2015 Feb;106(1):1-7. [PubMed]

- [14] Carlesso LC, Macdermid JC, Gross AR, Walton DM, Santaguida PL. Treatment preferences amongst physical therapists and chiropractors for the management of neck pain: results of an international survey. *Chiropr Man,Therap.* 2014 Mar 24;22(1):11. [PMC free article] [PubMed]
- [15] Ramirez MM, Brennan GP. Using the value-based care paradigm to compare physical therapy access to care models in cervical spine radiculopathy: a case report. *Physiother Theory Pract.* 2019 Feb 18;:1-9. [PubMed]
- [16] van der Windt DA, Simons E, Riphagen II, Ammendolia C, Verhagen AP, Laslett M, Devillé W, Deyo RA, Bouter LM, de Vet HC, Aertgeerts B. Physical examination for lumbar radiculopathy due to disc herniation in patients with low-back pain. *Cochrane Database Syst Rev.* 2010 Feb 17;(2):CD007431. [PubMed]
- [17] Shankar A etal , Tropical spastic paraparesis and Ayurveda *ARC Journal of Clinical Case Reports* Volume 5, Issue 2, 2019, PP 11-17

Citation: Dr. Avinash Shankar, et.al., (2019). "Radiculitis and its Current Approach". *International Journal of Clinical Chemistry and Laboratory Medicine (IJCLM)*, 5(2), pp. 25-34, DOI: <http://dx.doi.org/10.20431/2455-7153.0502005>.

Copyright: © 2019 Authors. This is an open-access article distributed under the terms of the Creative Commons Attribution License, which permits unrestricted use, distribution, and reproduction in any medium, provided the original author and source are credited.