

A Rare Case of a Traumatic Pseudoaneurysm of the Superior Cerebellar Artery Treated by Embolisation with Nbca

Luis Suazo¹, Hubiel Lopez¹, Herwin Speckter², Peter Stoeter^{2*}

¹Department of Interventional Neurosurgery, CEDIMAT, Plaza de la Salud, Santo Domingo, Dominican Republic

²Department of Radiology, Plaza de la Salud, Santo Domingo, Dominican Republic

***Corresponding Author:** Peter Stoeter, Department of Radiology, Plaza de la Salud, Santo Domingo, Dominican Republic. Email: peter.stoeter@gmx.de.

Abstract: We report the rare case of a traumatic pseudoaneurysm of a branch of the superior cerebellar artery, which manifested itself by a subtentorial hemorrhage with a delay of three weeks after the trauma. The pseudoaneurysm was treated successfully by selective NBCA embolization including the occlusion of the parent artery. The intervention was tolerated well without further neurological deterioration. The case demonstrates that parent vessel occlusion is a valid treatment option in these rare pseudoaneurysms especially when the vascular territory supplied by this vessel has already been compromised before the intervention.

Keywords: Posttraumatic pseudoaneurysm, superior cerebellar artery, subtentorial hemorrhage, embolisation, parent vessel occlusion

1. BACKGROUND

Traumatic pseudoaneurysms of the superior cerebellar artery are rare findings. Since 1990, when Quatrocchi et al. [1] found just 3 cases in the literature, only few more cases have been reported [2-5]. Here we describe a traumatic pseudoaneurysm of the superior cerebellar artery in combination with an intracerebral bleeding due to a severe head trauma which was treated successfully by arterial glue embolization.

2. CASE PRESENTATION

The patient, a 26 year old male, was admitted to hospital after a severe head trauma, caused by a cutting knife on his left eye. He was admitted in Glasgow Coma Scale 13/15. CT showed skull base fractures, external pneumatocephalus, brain stem contusion and an intracerebral hemorrhage in the vermis and the right part of the pons

(Fig.1). After 2 weeks, the patient had stabilized and could be extubated. After a further week however, he deteriorated due to a new bleeding at the same location, but with breaking into the ventricular system and progressive hydrocephalus, which needed shunting. Because of this second and “unexplained” hemorrhage, angiography was performed which showed an aneurysm arising from the parapontine segment of the vermian branch of the right superior cerebellar artery (Fig. 2). The distal localization of the aneurysm and the small caliber of the parent vessel did not allow coiling or stenting, and the aneurysm and parent artery were occluded by selective n-butyl-acrylate embolization. The outcome was stable, not showing any deterioration in his neurological status. Control CT scan showed no further brain stem damage or cerebellar infarct.

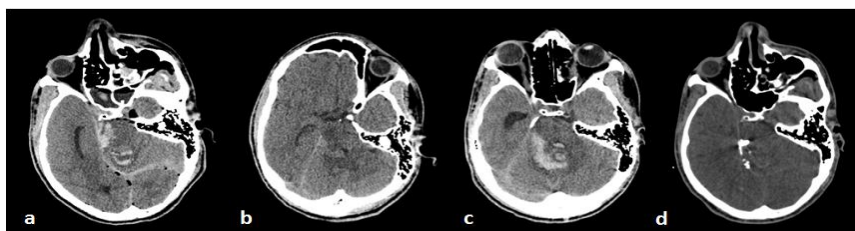


Figure1. CTs of day of trauma (a) and follow-up (b-d). The initial bleeding into the cerebellar vermis and upper part of the pons (a) has resolved after 11 days (b). 6 days later, a re-bleeding at the same localization causes ventricular congestion (c). One day after embolisation, the pseudoaneurysm and its parent branch are occluded by glue (d).

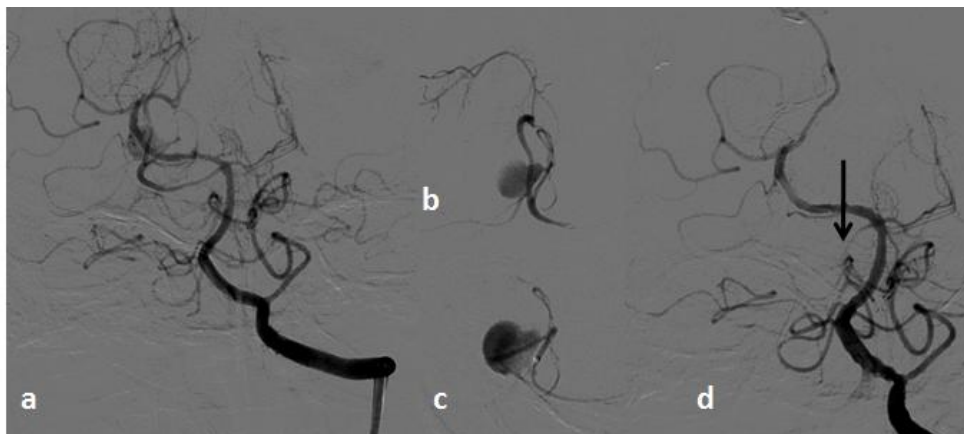


Figure 2. Left vertebral arteriography showing the pseudoaneurysm originating from a parapontine branch of the superior cerebellar artery (b). Position of the catheter tip just before embolisation (c) and post-interventional vertebral angiography showing subtotal occlusion of the parent artery (d, arrow).

3. DISCUSSION

Posttraumatic intracranial aneurysms, in which the adventitia is still preserved, and pseudoaneurysms with a disruption of the complete vascular wall, usually affect the anterior circulation [6]. Treatment may be surgical or interventional by placement of stents or flow diverters, but coil packing of aneurysms above the carotid sinus may be difficult because of the absence of a vascular wall [7, 8]. Although glue injection might result in parent vessel occlusion, it could be tolerated well in special conditions as in PICA aneurysms, if brainstem perforators are not involved [9].

Among all posttraumatic cerebral vascular injuries, formation of a superior cerebellar artery pseudoaneurysm is an especially rare complication of head trauma and may be caused by a laceration of the arterial wall caused by the free edge of the tentorium.[2] Delayed or recurrent posttraumatic hemorrhage in the upper parts of the cerebellum may be a diagnostic hint to perform angiography [1]. As in supratentorial and PICA pseudoaneurysms [10], treatment is indicated because a case of late catastrophic rupture has been reported [4].

4. CONCLUSION

The case demonstrates that in pseudoaneurysms of the superior cerebellar artery, interventional occlusion of the lesion and the parent vessel by injection of glue is a valid treatment option, especially when the vascular territory supplied by this vessel has already been compromised before the intervention.

REFERENCES

- [1] Quattrochi KB, Nielsen SL, Poirier V, Wagner FC Jr. Traumatic aneurysm of the superior cerebellar artery: case report and review of the literature. *Neurosurgery*. 1990; 27:476-479.
- [2] Proust F, Callonec F, Bellow F, Laquerriere A, Hannequin D, Fréger P. Tentorial edge traumatic aneurysm of the superior cerebellar artery. Case report. *J Neurosurg*. 1997; 87:950-954.
- [3] Altman DA, Hui FK, Tumialán LM, Cawley CM. Subintimal hemorrhage in an unruptured superior cerebellar artery aneurysm: prelude to rupture: case report. *Neurosurgery*. 2008; 63:E368-9; discussion E369. Doi :10.1227/01.NEU.0000320423.40846. A1.
- [4] Ong CK, Ong MT, Lam DV, Wenderoth JD. Catastrophic delayed rupture of a traumatic aneurysm of the distal superior cerebellar artery in a child. *J Clin Neurosci*. 2010; 17:515-517. doi:10.1016/j.jocn. 2009.06.041.
- [5] Paiva WS, Andrade AF, Stermann Neto H, de Amorim RL, Caldas JG, Teixeira MJ. Traumatic pseudoaneurysm of the superior cerebellar artery. *J Trauma Acute Care Surg*. 2012;72:E115. doi:10.1097/TA.0b013e318238bee5.
- [6] Miley JT, Rodriguez GJ, Qureshi AI. Traumatic intracranial aneurysm formation following closed head injury. *J Vasc Interv Neurol* 2008; 1:79-82. PMID: 3317295
- [7] Moon TH, Kim SH, Lee JW, Huh SK. Clinical analysis of traumatic cerebral pseudoaneurysms *Korean J Neurotrauma* 2015; 11:124-130. Doi:org/10.13004/kjnt. 2015.11.2. 124
- [8] Liu P, Yang M, Cai M, Qin J, Pan L. Treatment of pediatric traumatic intracranial pseudoaneurysm using endovascular covered stent: three case reports. *World Neurosurg*. 2016;

- 88:693.e1-6. doi: 10.1016/ wneu .2 01 5 . 12.037
- [9] Kumar A, Ahuja CK, Khandelwal N, Mathuriya SN. Endovascular *N*-Butyl cyanoacrylate glue embolization of traumatic anterior cerebral artery pseudo-aneurysm. *Neurol India* 2012; 60:663-665. doi: 10.4103/0028-3886.105216
- [10] Sedat J, Chau Y, Mahagne MH, Bourg V, Lonjon M, Paquis P. Dissection of the posteroinferior cerebellar artery: clinical characteristics and long-term follow-up in five cases. *Cerebrovasc Dis.* 2007; 24:183-190. doi: 10.1159/000104475

Citation: Luis Suazo, Hubiel Lopez, Herwin Speckter, Peter Stoeter. *A Rare Case of a Traumatic Pseudoaneurysm of the Superior Cerebellar Artery Treated by Embolisation with Nbca.* *ARC Journal of Radiology and Medical Imaging.* 2017; 2(2): 4-6.

Copyright: © 2017 Authors. This is an open-access article distributed under the terms of the Creative Commons Attribution License, which permits unrestricted use, distribution, and reproduction in any medium, provided the original author and source are credited.