

A Challenging Case of Acute Subarachnoid Haemorrhage in a Patient with 10 Intracranial Aneurysms

**Culleton S^a, KokHK^{a,*}, Looby S^a, Brennan P^a, O'Hare A^a, Javadpour M^b,
Thornton J^a, Asadi H^{a,c}**

^aNeurointerventional and Interventional Radiology Service,

Department of Radiology, Beaumont Hospital, Dublin 9, Ireland.

^bDepartment of Neurosurgery, Beaumont Hospital, Dublin 9, Ireland.

^cSchool of Medicine, Faculty of Health, Deakin University, Pigdons Road,
Waurin Ponds, VIC 3216, Australia.

*terrykok@gmail.com

Abstract: *Acute subarachnoid haemorrhage can lead to significant morbidity for patients including death, therefore ruptured aneurysms require prompt treatment.*

In this article, we present a case of acute subarachnoid haemorrhage due to a ruptured anterior communicating artery, in a patient with multiple other intracranial aneurysms, also requiring treatment.

This case demonstrates the use of a number of endovascular techniques in combination with open clipping to treat the multiple complex aneurysms.

1. INTRODUCTION

The successful management of a ruptured intracranial aneurysm requires exclusion of the aneurysm from the intracranial circulation, thereby preventing future risk of haemorrhage. Endovascular techniques are associated with lower morbidity and mortality compared with open surgery [1]. Despite many advances in the management of ruptured aneurysms and endovascular treatments, there still remains significant morbidity and mortality as a consequence of an acute subarachnoid haemorrhage, and cases can vary in complexity depending on the size, number and location of aneurysms.

This case highlights how the management of multiple intracranial aneurysms can pose challenges to the clinician and interventionist. Not only did the acutely ruptured aneurysm require immediate coiling but for each remaining aneurysm, a specific treatment plan had to be defined, requiring a combination of endovascular and open neurosurgical techniques.

2. CASE REPORT

A 58 year-old right-handed woman presented with a one-day history of acute onset severe frontal headache and confusion. She had no prior medical or surgical history. Her Glasgow Coma Scale was 14 at arrival to the Emergency Department and she had no focal neurologic deficit on clinical examination.

Non-contrast computed tomography (CT) scan of the brain at presentation showed acute subarachnoid haemorrhage in the interhemispheric fissure and a left frontal lobe intraparenchymal haematoma with extension into the ventricular system (Figure 1) consistent with a Fisher grade 4 subarachnoid haemorrhage.

A catheter cerebral angiogram was subsequently performed under general anaesthesia to assess and treat the suspected ruptured aneurysm, showing an irregularly lobulated anterior communicating artery (ACOM) aneurysm (Figure 2), concordant with the pattern of haemorrhage on CT, accounting for the acute presentation. However, it also revealed 9 further intracranial aneurysms throughout the circle of Willis (Figure 2).

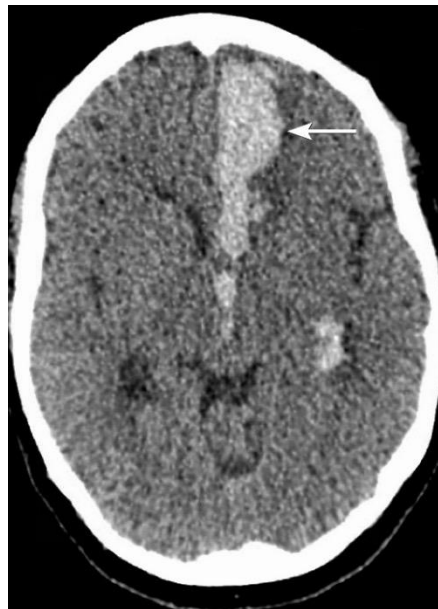

Figure1. CT brain shows subarachnoid along the interhemispheric fissure (white arrow) with extension into the third and left lateral ventricle.

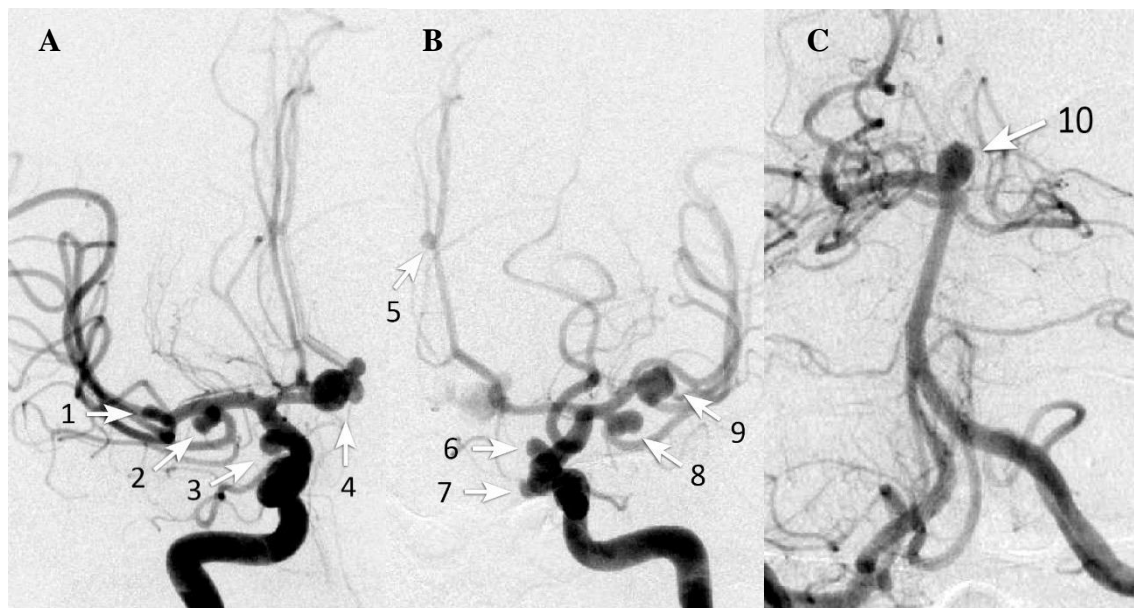


Figure2. Right and left ICA as well as left vertebral catheter angiograms (A, B & C respectively) demonstrating multiple intracranial aneurysms, including the multiloculated ruptured anterior communicating artery aneurysm:

1 & 9 – MCA bifurcation, 2 & 8 – Anterior temporal, 3 – PCOM, 4 – ACOM, 5 – Pericallosal, 6 – Supraorbital, 7 – Transitional, 10 – Basilar.

3. MANAGEMENT STRATEGY

The ACOM aneurysm was treated successfully by endovascular coiling (Figure 3). She recovered well from the acute episode with no post-procedural complications or neurological deficit. The basilar tip aneurysm was also coil embolised during the recovery period in hospital (Figure 3).

The treatment decision regarding the remaining 8 aneurysms is challenging and a combination of endovascular and neurosurgical techniques will be required.

The two right middle cerebral artery (MCA) and two paraclinoid internal carotid artery (ICA) aneurysms are likely amenable to balloon assisted coil embolisation. Next, the two left MCA aneurysms demonstrate wide necks and will be treated with surgical clipping, and finally with full antiplatelet premedication on board, the two remaining left sided transitional and paraclinoid wide neck ICA aneurysms are to be stented for flow diversion.

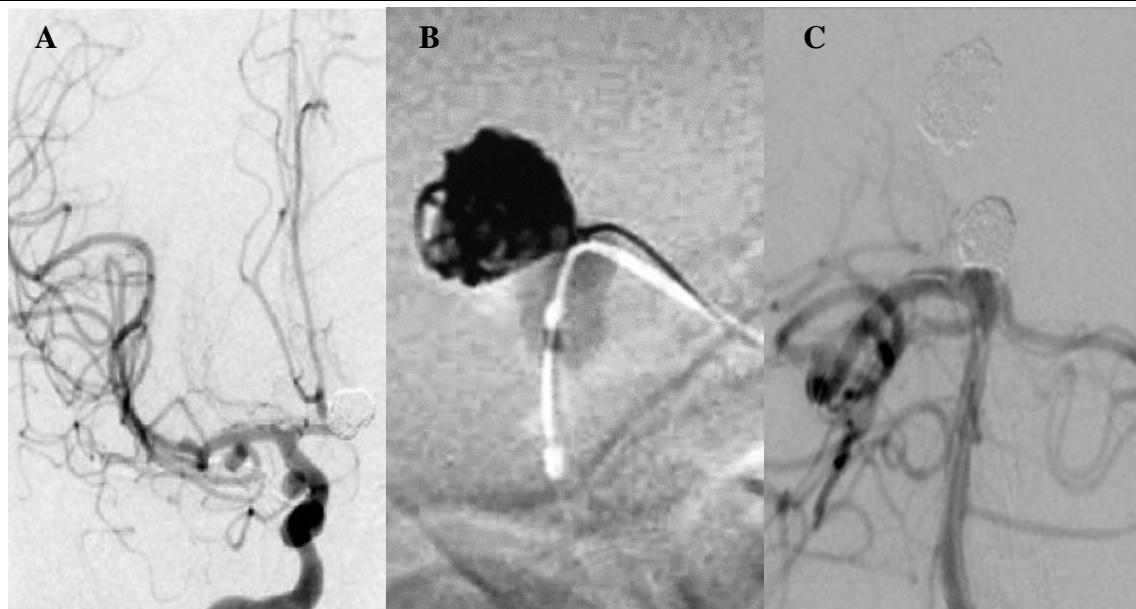


Figure 3. Cerebral angiogram showing the ruptured anterior communicating artery aneurysm, successfully secured (A), and balloon assisted (B) coiling of the basilar aneurysm (C).

4. DISCUSSION

Cerebral aneurysms and subarachnoid haemorrhage have a complex clinical course. The majority of aneurysms have an annual rupture risk of less than 1% [2,3]. However, rupture carries a high mortality rate of approximately 40% [4,5]. Multiple intracranial aneurysms have been shown to have a worse outcome compared to single aneurysms after subarachnoid haemorrhage [6,7], and up to 20-34% of patients may have multiple intracranial aneurysms [6,8].

Endovascular intervention is now considered first line treatment for intracranial aneurysms. The International Subarachnoid Aneurysm Trial demonstrated that endovascular coiling was associated with lower mortality and morbidity rates compared to open neurosurgical clipping [1]. Advances in both equipment and techniques have made endovascular treatment of even dissecting and wide neck aneurysms possible [9,10]. Such advances include three dimensional coils, micro-stents and balloons, flow diverting stents and the introduction of balloon and stent assisted coiling [9,10]. Almost the entire spectrum of these advanced endovascular techniques will be used in managing the various aneurysms encountered in this case.

This case highlights the need for a meticulous, multidisciplinary management strategy for each aneurysm, taking into consideration the urgency of treatment and suitability to different therapeutic techniques. Although not unreported, multiple aneurysms of this number in a single individual is very rare and a combined endovascular and surgical approach is often required in a timely fashion for treatment.

REFERENCES

- [1] Molyneux AJ, Kerr RS, Yu LM, Clarke M, Sneade M, Yarnold JA, Sandercock P; International Subarachnoid Aneurysm Trial (ISAT) Collaborative Group. International Aneurysm Trial (ISAT) of neurosurgical clipping versus endovascular coiling in 2143 patients with ruptured intracranial aneurysms: a randomised comparison of effects on survival, dependency, seizures, rebleeding, subgroups and aneurysm occlusion. *Lancet* 2005; 366(9488):809-17.
- [2] Juvela S, Poussa K, Porras M. Factors affecting formation and growth of intracranial aneurysms a long-term follow-up study. *Stroke*; 2001; 32(2):485-91.
- [3] Wiebers DO, Whisnant JP, Houston 3rd J, Meissner I, Brown Jr R, Piepgras DG et al. International Study of Enruptured Intracranial Aneurysms Investigators. Unruptured intracranial aneurysms: Natural history, clinical outcome, and risks of surgical and endovascular treatment. *Lancet* 2003; 362(9378):103-10.
- [4] Nieuwkamp DJ, Setz LE, Algra A, Linn FH, de Rooij NK, Rinkel GJ. Changes in case fatality of aneurysmal subarachnoid haemorrhage over time, according to age, sex, and region: a meta-analysis. *Lancet Neurology* 2009; 8(7):635-42.

- [5] Steiner T, Juvela S, Unterberg A, Jung C, Forsting M, Rinkel GJ. European stroke organisation guidelines for the management of intracranial aneurysms and subarachnoid haemorrhage. *Cerebrovasc Dis.* 2013; 35(2):93-112.
- [6] Juvela S. Risk factors for multiple intracranial aneurysms. *Stroke* 2000; 31(2):392-397.
- [7] Rinne J, Hernesniemi J, Puranen M, Saari T. Multiple intracranial aneurysms in a defined population: prospective angiographic and clinical study. *Neurosurgery* 1994; 35:803– 808.
- [8] Rinne J, Hernesniemi J, Niskanen M, Vapalahti M. Management outcome for multiple intracranial aneurysms. *Neurosurgery* 1995; 36(1):31–38.
- [9] Higashida RT, Smith W, Gress D, Urwin R, Dowd CF, Balousek PA et al. Intravascular stent and endovascular coil placement for a ruptured fusiform aneurysm of the basilar artery: case report and review of the literature. *J Neurosurg* 1997; 87(6):944-9.
- [10] Phatouros CC, Sasaki TY, Higashida RT, Malek AM, Meyers PM, Dowd CF, Haibach VV. Stent-supported coil embolisation: the treatment of fusiform and wide-necked aneurysms and pseudoaneurysms. *Neurosurgery* 2000; 47(1):107-15.