

## A Case Study of Severe Manifestations of Mucopolysaccharidosis type I; Hurler Syndrome

<sup>1</sup>Dr Muhammad Shehzad Khan Wazir, <sup>2</sup>Hisham Khan, <sup>3</sup>Muhammad Abdullah, <sup>4</sup>Pashma Wazir, <sup>5</sup>Shanzay Wazir, <sup>6</sup>Ahmad Ali

<sup>1</sup>Pakistan Institute of Medical Sciences Pakistan

<sup>2</sup>Shifa College of Medicine Pakistan

<sup>3</sup>Rehman Medical College Pakistan

<sup>4</sup>Islamabad Medical and Dental College Pakistan

<sup>5</sup>Shifa College of Dentistry Pakistan

<sup>6</sup>Ayub Medical College Pakistan

**\*Corresponding Author:** Dr Muhammad Shehzad Khan Wazir, Pakistan Institute of Medical Sciences Pakistan, E-mail: [shehzad.khan.wazir@gmail.com](mailto:shehzad.khan.wazir@gmail.com)

### Abstract:

Hurler syndrome (mucopolysaccharidosis type 1) is a rare autosomal recessive disorder of inborn error of metabolism. It is a lysosomal storage disease in which deficiency of enzyme  $\alpha$ -L-iduronidase leads to the accumulation of glycosaminoglycans GAGs (heparin sulfate, dermatan sulfate) in various organs of the body that leads to impairment of different organ systems. Such children appear normal at birth but later on suffer from mental and physical deterioration leading to death from cardiorespiratory failure before the second decade of life. We report a seven year old girl with severe skeletal, neurological, ophthalmologic, oro-dental and radiological findings of this disease.

**Keywords:** Hurler syndrome, mucopolysaccharidoses, dysostosis multiplex, endocrinology, lysosomes, GAGs.

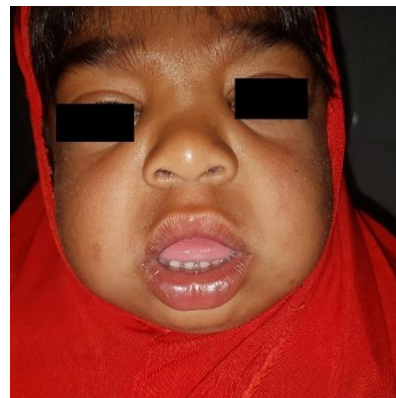### 1. INTRODUCTION

Mucopolysaccharidosis are an inborn heterogeneous group of rare metabolic disorders inherited as autosomal recessive traits, due to deficiency or absence of lysosomal hydrolase iduronidase activity<sup>1</sup>. The defect has been mapped to the chromosome band 4p16.3<sup>2</sup>. The most common and severe form of mucopolysaccharidosis is Hurler syndrome (MPS I - H). A wide range of phenotypes result from deficiency of this enzyme including Hurler's (severe), Scheie's (mild) and Hurler-Scheie (intermediate) syndromes<sup>3</sup>. Hurler Syndrome incidence has been reported to be 1:100,000 per child birth<sup>4</sup>.

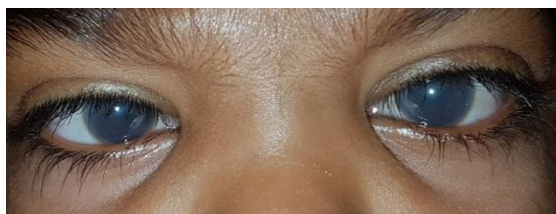### 2. CASE REPORT

A seven year old child presented to our healthcare department with abdominal distention and fever. Examination of the child was consistent with coarse facial features like depressed and broad nasal bridge, flaring of

both nostrils, prominent supra orbital rim bilaterally, ptosis of eye balls with ocular hypertelorism, thick eye lids and full and thick lips. Other findings included developmental delay, corneal clouding, protruding tongue, abdominal distention consistent with hepatosplenomegaly and umbilical hernia. (figure 1a, 1b)



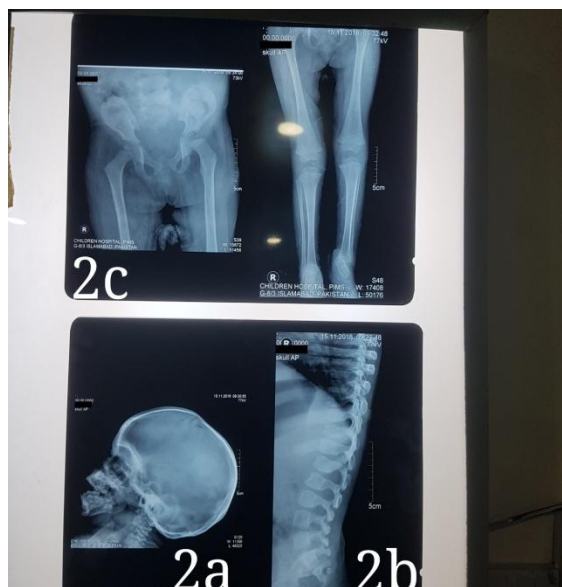
**Figure 1(a).** Showing broad nasal bridge, prominent orbital rims, nostril flaring and hypertelorism



**Figure 1(b).** Clouding of corneas

Base line investigation showed normal TLC, platelet and retic count with low hemoglobin of 8.7mg/dl. Serum electrolytes, blood glucose levels, renal function tests and urinalysis were in normal range. Liver function tests were unremarkable except for ALP of 365 IU/L. Thyroid function tests showed low total T3 with normal TSH and free T4 levels.

Skeletal survey was consistent with dysostosis multiplex. Intraoral examination revealed a large tongue, interdental spacing with thick gingivae. Skeletal survey showed variable degree of osteopenia with macrocephaly, thick vault with ground glass capacity and J shaped sella turcica (Figure:2a). Anterior beaking aspect, abnormal shaped of vertebral bodies due to hypoplasia and kyphosis were observed in the radiographs (Figure:2b). Other radiographic findings were hip dysplasia, underdeveloped acetabula, rounded iliac wings, dysplastic femoral epiphysis and coxa valga (figure2c).

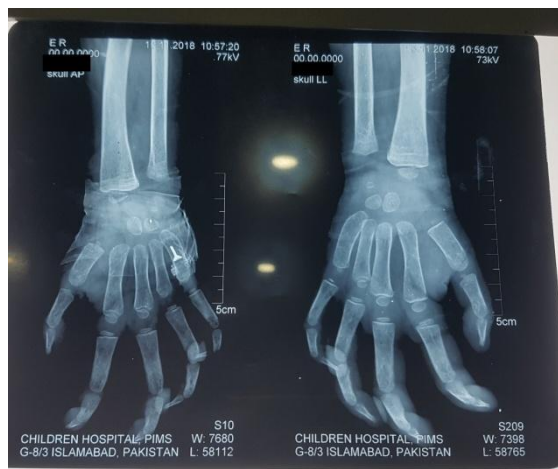

**Figure 2(a).** Radiograph showing J shaped sella turcica. **Figure 2(b).** Radiograph showing abnormal shaped of vertebral with hypoplasia and kyphosis. **Figure 2(c).** Radiograph showing hip dysplasia with rounded iliac wings.

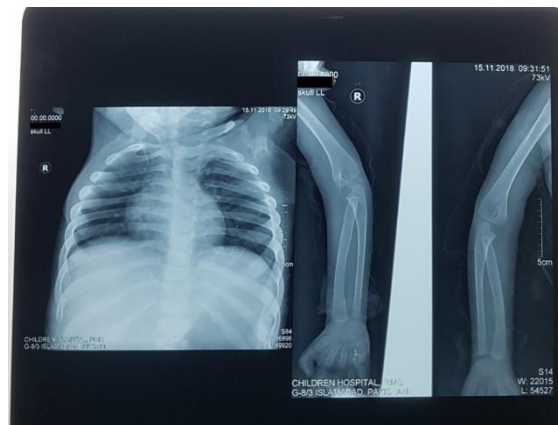
Hand wrist radiograph showed wide metacarpals with proximal pointing, irregular carpal bones,

ulnar hypoplasia and increased joint space at radioulnar joints (figure:3).

Chest radiograph (PA view) showed paddle shaped ribs, shortened and thickened clavicles (figure:4). Echocardiography showed Mitral leaflet prolapse with mitral regurgitation grade II.



**Figure 3.** Hand wrist radiograph showing wide metacarpals with proximal pointing, irregular carpal bones, ulnar hypoplasia with increased joint space at radioulnar joints



**Figure 4.** Chest radiograph PA view showing paddle shaped ribs with thickened clavicles

Ultrasound of abdomen was consistent with hepatosplenomegaly and umbilical hernia. Blood was investigated for alpha-L iduronidase enzyme activity to confirm the diagnosis of MPS I H. Fluorometric test confirmed the diagnosis of MPS I H (Hurler Syndrome).

### 3. DISCUSSION

Glycosaminoglycans degradation is carried out by enzyme  $\alpha$ -L-Iduronidase and its absence results in the accumulation of substrates like heparan sulphate and dermatan sulfate in lysosomes of various tissues of the body resulting in developmental delay, skeletal

malformations, corneal clouding, organomegaly, oro-facial anomalies and problems in the cardiorespiratory system<sup>5</sup>. Mucopolysaccharidosis is inherited in an autosomal recessive fashion

except hunter syndrome which is X linked<sup>6</sup>. The type of GAGs stored and the classification of disease depend on the specific enzyme deficiency<sup>7</sup>. Table 1 shows the different types.

**Table 1.** Mucopolysaccharidosis table showing its different types and respective enzyme deficiency, inheritance pattern and gene locations

MPS	Name	Increased GAGs	Inheritance	Enzyme deficiency	Gene location
I	Hurler, Hurler-Scheie or Scheie	HS + DS	autosomal recessive	$\alpha$ -duronidase	4p16.3
II	Hunter	HS + DS	X-linked recessive	Iduronate sulfatase	Xq28
III A	Sanfilippo A	HS	autosomal recessive	Heparan-N-sulfatase	17q25.3
III B	Sanfilippo B	HS	autosomal recessive	$\alpha$ -N-acetylglucosaminidase	17q21.1
III C	Sanfilippo C	HS	autosomal recessive	AcetylCoA $\alpha$ - glucosamine acetyltransferase	14p21
III D	Sanfilippo D	HS	autosomal recessive	N-acetylglucosamine 6-sulfatase	12q14
IV A	Morquio A	KS	autosomal recessive	Galactosamine-6-sulfate sulfatase	16q24.3
IV B	Morquio B	KS	autosomal recessive	$\beta$ -galactosidase	3p21.3
(V)	Scheie syndrome, initially proposed as type V, was recognized to be the attenuated end of the MPS I spectrum				
VI	Maroteaux-Lamy	DS	autosomal recessive	N-acetylgalactamine 4-sulfatase	5q11-q13
VII	Sly	HS + DS	autosomal recessive	$\beta$ -glucuronidase	7q21.11
(VIII)	An enzyme defect was found and proposed as MPS VIII, but shortly thereafter recognized as a laboratory pitfall; the proposal was withdrawn				
IX	Natowicz	Hyaluronan	autosomal recessive	Hyaluronidase 1	3p21.3

In severe forms of mucopolysaccharidosis, average lifespan is one to two decades<sup>8</sup>. A combination of clinical picture and analysis of urinary GAGs is usually performed to achieve the diagnosis. Definitive diagnosis is usually possible through measuring enzyme activity in cultured fibroblasts or leukocytes<sup>6</sup>.

Treatment consists mainly of symptomatic and supportive care. In recent years the development of new therapies like enzyme replacement therapies, substrate inhibition therapy and hematopoietic cell transplantation have changed the treatment of these patients. This has shifted treatment from supportive to curative and has improved the duration and quality of life of these patients<sup>9,10</sup>.

Radiography features include J shaped sella turcica which is characteristic but not diagnostic for mucopolysaccharidosis. In radiographs of thorax, the main abnormality concerns the ribs, which can be “paddle-shaped” or “oar-shaped” due to anterior arch widening and tapering of the posterior arches. Other common modifications are small scapulae, usually with flattening of the glenoid cavities, a short sternum and short and thickened aspect of the clavicles<sup>11</sup>. In the spine, vertebral body deformities are common with thoracolumbar gibbus. These deformities can lead to compression of spinal cord and emerging roots<sup>12</sup>. The most common radiological features in the pelvis are rounded iliac wings and inferior tapering of the ileum (figure:2c)<sup>13</sup>. The long bones are often characterized by several

alterations. Diaphysis are shortened and curved in the distal part; the epiphyses are slightly hypoplastic and thinned cortically with osteoporosis<sup>14</sup>. In appendicular skeleton features that can be found are the notching of the proximal part of the humerus, the long and narrow aspect of the femoral neck with underdeveloped acetabula (figure:2c), and the hypoplasia of the lateral tibial hemiplate, resulting in genu valgum. Almost all forms of MPS show distortion of the hand (figure:3) and foot structure. Carpal and tarsal bones are hypoplastic and irregularly shaped; the metacarpal bones are proximally pointed, shortened and thickened. This leads to compromised functionality of hands and claw hand deformity due to failure of complete extension of fingers<sup>15</sup>. At the craniovertebral junction atlantoaxial instability can also occur<sup>12</sup>.

Developmental delay is a major manifestation of the disease which can be explained due to brain atrophy and neuronal death secondary to accumulation of GAG in neuronal tissues. The neuronal death could be explained by ischemic damages due to the progressive accumulation of GAG in blood vessels<sup>16</sup>. Hydrocephalus may also accompany brain atrophy.

#### 4. CONCLUSION

Knowledge of clinical and radiological features is important for diagnosis. Definitive diagnosis is usually obtained by lab analysis. Early recognition is important for monitoring the chronic and progressive course of the disease. It

is also important for medical and surgical planning and for assessing the impact of therapy.

### REFERENCES

- [1] Worth HM. Hurler's syndrome: A study of radiologic appearances in the jaws. *Oral Surgery, Oral Medicine, Oral Pathology*. 1966 Jul 1;22(1):21-35.
- [2] Bjoraker KJ, Delaney K, Peters C, Krivit W, Shapiro EG. Long-term outcomes of adaptive functions for children with mucopolysaccharidosis I (Hurler syndrome) treated with hematopoietic stem cell transplantation. *Journal of Developmental & Behavioral Pediatrics*. 2006 Aug 1;27(4):290-6.
- [3] Muenzer J, Wraith JE, Clarke LA. International Consensus Panel on Management and Treatment of Mucopolysaccharidosis I (2009) Mucopolysaccharidosis I: management and treatment guidelines. *Pediatrics*.; 123(1):19-29.
- [4] Hingston EJ, Hunter ML, Hunter B, Drage N. Hurler's syndrome: dental findings in a case treated with bone marrow transplantation in infancy. *International journal of paediatric dentistry*. 2006 May; 16(3):207-12.
- [5] James WD, Elston D, Berger T. *Andrew's Diseases of the Skin E-Book: Clinical Dermatology*. Elsevier Health Sciences; 2011 Mar 21, pp 544.
- [6] Muenzer J. The mucopolysaccharidoses: a heterogeneous group of disorders with variable pediatric presentations. *The Journal of pediatrics*. 2004 May 1;144(5):S27-34.
- [7] Wraith JE. The mucopolysaccharidoses: a clinical review and guide to management. *Archives of disease in childhood*. 1995 Mar; 72(3):263.
- [8] Coutinho MF, Lacerda L, Alves S. Glycosaminoglycan storage disorders: a review. *Biochemistry research international*. 2012; 2012.
- [9] Beck M. New therapeutic options for lysosomal storage disorders: enzyme replacement, small molecules and gene therapy. *Human genetics*. 2007 Mar 1; 121(1):1-22.
- [10] Polgreen LE, Miller BS. Growth patterns and the use of growth hormone in the mucopolysaccharidoses. *Journal of pediatric rehabilitation medicine*. 2010 Jan 1; 3(1):25-38.
- [11] Glass RB, Norton KI, Mitre SA, Kang E. Pediatric ribs: a spectrum of abnormalities. *Radiographics*. 2002 Jan; 22(1):87-104.
- [12] Palmucci S, Attinà G, Lanza ML, Belfiore G, Cappello G, Foti PV, Milone P, Di Bella D, Barone R, Fiumara A, Sorge G. Imaging findings of mucopolysaccharidoses: a pictorial review. *Insights into imaging*. 2013 Aug 1;4(4):443-59.
- [13] Eich GF, Babyn P, Giedion A. Pediatric pelvis: radiographic appearance in various congenital disorders. *Radiographics*. 1992 May; 12(3):467-84.
- [14] Lachman R, Martin KW, Castro S, Basto MA, Adams A, Teles EL. Radiologic and neuroradiologic findings in the mucopolysaccharidoses. *Journal of pediatric rehabilitation medicine*. 2010 Jan 1; 3(2):109-18.
- [15] Mankin HJ, Jupiter J, Trahan CA. Hand and foot abnormalities associated with genetic diseases. *Hand*. 2011 Mar;6(1):18-26.
- [16] Lee C, Dineen TE, Brack M, Kirsch JE, Runge VM. The mucopolysaccharidoses: characterization by cranial MR imaging. *American journal of neuroradiology*. 1993 Nov 1;14(6):1285-92.

**Citation:** Dr Muhammad Shehzad Khan Wazir, Hisham Khan, Muhammad Abdullah, Pashma Wazir, Shanzay Wazir, Ahmad Ali. *A Case Study of Severe Manifestations of Mucopolysaccharidosis type I; Hurler Syndrome*. *ARC Journal of Pediatrics*.2020; 6(1):4-7.[doi:dx.doi.org/10.20431/2455-5711.0601002](https://doi.org/10.20431/2455-5711.0601002).

**Copyright:** © 2020 Authors. This is an open-access article distributed under the terms of the Creative Commons Attribution License, which permits unrestricted use, distribution, and reproduction in any medium, provided the original author and source are credited.