

## Acute Pancreatitis in an Elderly Woman: Annular Pancreas

Maddalena Zippi<sup>1\*</sup>, Chiara Marzano<sup>1</sup>, Wandong Hong<sup>2</sup>, Sirio Fiorino<sup>3</sup>, Giuseppe Occhigrossi<sup>1</sup>

<sup>1</sup>Unit of Gastroenterology and Digestive Endoscopy, Sandro Pertini Hospital, Rome, Italy

<sup>2</sup>Department of Gastroenterology and Hepatology, The First Affiliated Hospital of Wenzhou Medical University, Wenzhou, Zhejiang, China

<sup>3</sup>Unit of Internal Medicine, Maggiore Hospital, Local Health Unit of Bologna, Bologna, Italy

**\*Corresponding Author:** Maddalena Zippi, Md, PhD, Via dei Monti Tiburtini 385, 00157 Rome, Italy, Email: maddyzip@yahoo.it

### Abstract

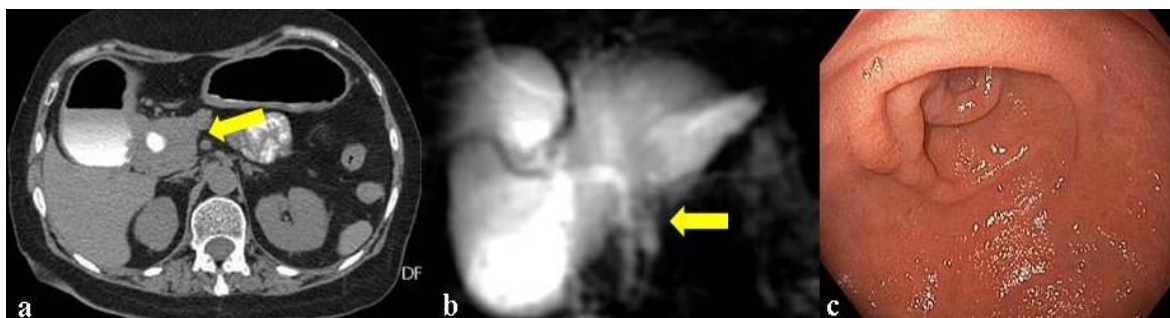
The annular pancreas is a rare congenital malformation of the organ. It generally occurs during the first years of life. Its manifestations in adulthood are rare and generally appear with symptoms of duodenal obstruction. We present the case of a 77-year-old woman, came to our attention for acute pancreatitis due to an annular pancreas, successfully treated surgically.

**Keywords:** Acute pancreatitis, annular pancreas, computed tomography (CT), magnetic resonance cholangiopancreatography (MRCP), surgery.

### CASE REPORT

A 77-year-old woman was admitted to our Unit, due to typical pancreatic abdominal pain and vomiting. Laboratory test showed only an elevation of pancreatic enzymes: amylase 860 (normal 30-110 U/L) and lipase 1.250 (normal 23-300 U/L). Therefore a diagnosis of acute pancreatitis was made. An abdominal computed tomography (CT) with Gastrografin found a sub-stenosant complete annular pancreatic solid tissue surrounding the lower portion of the second duodenal one, resulting in marked duodenal retro-dilatation up to the bulb (**Figure 1a, yellow arrow**). A magnetic resonance of the abdomen confirmed the findings of the CT and, in addition, the cholangiopancreatography

(MRCP) showed an alteration of the main pancreatic duct. It had a course anterior to the common bile duct and formed almost a loop with a slight proximal dilatation (**Figure 1b, yellow arrow**). The patient was treated with bowel rest, broad spectrum antibiotics and gabexatemesilate until the normalization of the pancreatic function. Moreover, insertion of a nasogastric tube was performed under gastroscopy, which confirmed the stenosis of the second portion of the duodenum (**Figure 1c**) and the presence of some erosions due to the stasis of ingesta. Therefore, a duodeno-jejunal by-pass was performed. Eight days after the surgical intervention, she was discharged in good health and without any intestinal disorder.



**Figure1**

Annular pancreas (AP), a rare congenital disease, has a not well defined prevalence due to the fact that this condition may be asymptomatic. Data emerging from autopsy series show a prevalence ranging from 5 to 15

per 100,000 adults with a preference for the male sex [1, 2]. The few cases diagnosed in the elderly, generally, present symptoms due to gastric outlet obstruction [3]. In a small percentage of these ones diagnosed at an

advanced age, acute pancreatitis may be the initial expression of the underlying congenital malformation [4].

#### REFERENCES

- [1] Tas A, Köklü S, Kocak E, Akbal E, Ergul B. An Unusual Cause of Acute Pancreatitis: Annular Pancreas and Papillary Opening of the Cystic Duct. *Gut Liver*. 2012; 6(3):403-404. doi: 10.5009/gnl.2012.6.3.403
- [2] Chen YC, Yeh CN, Tseng JH. Symptomatic adult annular pancreas. *J Clin Gastroenterol*. 2003;36(5):446-450
- [3] Maker V, Gerzenshtein J, Lerner T. Annular pancreas in the adult: two case reports and review of more than century of literature. *Am Surg*. 2003;69(5):404-410
- [4] Bouslama K, Bedioui H, Maghrebi H. Acute pancreatitis revealing an annular pancreas. *Clin Res Hepatol Gastroenterol*. 2013;37(4):318-319

**Citation:** Maddalena Zippi, Chiara Marzano, Wandong Hong, Sirio Fiorino, Giuseppe Occhigrossi, *Acute Pancreatitis in an Elderly Woman: Annular Pancreas*. *ARC Journal of Hepatology and Gastroenterology*. 2018; 3(2):29-30

**Copyright:** © 2018 Authors. This is an open-access article distributed under the terms of the Creative Commons Attribution License, which permits unrestricted use, distribution, and reproduction in any medium, provided the original author and source are credited.