

Borderline Serous Fallopian Tube Tumor Coexisting with Serous Cystadenoma in Contralateral Ovary

Marcela Maluf Sanguinete¹, Loren Gécica Santos¹, Eddie Fernando Candido Murta¹,
Renata Margarida Etchebehere², Rosekeila Simões Nomelini^{3*}

¹Laboratory of Applied Sciences for Women (LaCam)/Department of Gynecology and Obstetrics,

²Surgical Pathology Subunity; Federal University of Triângulo Mineiro, Uberaba - MG, Brazil.

³Laboratory of Applied Sciences for Women (LaCam)/Department of Gynecology and Obstetrics, UFTM, Av. Getúlio Guaritá, s/n, Bairro Abadia, 38025-440 Uberaba-MG, Brazil, and Graduate Program in Gynecology and Obstetrics of the Ribeirão Preto Medical School of the University of São Paulo (FMRP-USP); Avenida Bandeirantes, 3900 – 8º andar Hospital das Clínicas. Monte Alegre, postal code 14049-900 – Ribeirão Preto – SP, Brazil.

***Corresponding Author:** Rosekeila Simões Nomelini, Laboratory of Applied Sciences for Women (LaCam)/Department of Gynecology and Obstetrics, UFTM, Av. Getúlio Guaritá, s/n, Bairro Abadia, 38025-440 Uberaba-MG, Brazil. ORCID ID: <https://orcid.org/0000-0001-6591-7619>

Abstract: Borderline fallopian tube tumors are rare; there are few published studies in the literature due to their rarity, unlike borderline ovarian tumors which are relatively more common. This is a case report of a borderline fallopian tube tumor diagnosed in a 50-year-old female patient after a laparotomy to remove an adnexal mass in the left ovary complemented with prophylactic contralateral salpingo-oophorectomy. Pathology showed a serous cystadenoma in an adnexal mass of the left ovary and borderline tumor of the contralateral fallopian tube.

Keywords: Fallopian tube borderline tumor; fallopian tube cancer; Serous borderline tumor.

Abbreviations: CA 125: cancer antigen 125; CA 15.3: cancer antigen 15.3; CA 19.9: cancer antigen 19.9; CEA: Carcinoembryonic Antigen human; hCG: human chorionic gonadotropin

1. INTRODUCTION

There is a paucity of information on borderline serous fallopian tube tumors in the literature due to their rarity, and limited experience on their clinical behavior. It is known that they have a low potential for malignancy because there is no stromal invasion. Borderline tube tumors are usually unilateral, being more frequent in the distal third of the fallopian tube. Symptoms are nonspecific, such as abdominal pain and dyspareunia. On physical examination, a pelvic mass may be found, or it may be an incidental finding in surgery [1,2].

The optimal treatment for borderline tubal tumors has not been established due to the rarity of the disease. However, it seems appropriate to treat these tumors as borderline ovarian tumors. It can be conservative or radical, according to the patient's reproductive desire. In the radical approach, hysterectomy, bilateral salpingo-oophorectomy, omentectomy and intraperitoneal inspection are

performed. In the conservative approach, salpingectomy or adnexectomy is performed on the affected side, with omentectomy and intraperitoneal inspection, maintaining the patient's follow-up [2-4].

2. CASE REPORT

A 50-year-old female patient was seen at the Pelvic Mass Outpatient Clinic of the Department of Gynecology and Obstetrics, due to an ultrasound finding of a complex adnexal cyst on the left, with a total volume of 80.5 cm³. She had nonspecific complaints of sporadic pelvic pain and dyspareunia. Serum tumor markers (CA 125, CA 15.3, CA 19.9, CEA, beta hCG, alpha-feto-protein) were normal.

Exploratory laparotomy was performed due to the persistence of the lesion. Upon inventory of the abdominal cavity, an ovarian mass was identified on the left, with a volume of approximately 100 ml, intact capsule, and

cystic content. Uterus and contralateral annex were without macroscopic changes. Left salpingo-oophorectomy was performed, and the material was sent for frozen section biopsy for evaluation, which showed serous cystadenoma in the left ovary. Due to the benignity of the condition, contralateral salpingo-oophorectomy was chosen as a prophylactic procedure in post-menopause, to reduce the risk of contralateral adnexal lesion.

The histopathological examination by paraffin showed serous cystadenoma in the left ovary

and borderline serous tumor of the right fallopian tube. Immunohistochemistry showed positive p53 immunostaining (figure 1). Subsequently, surgical complementation with hysterectomy, omentectomy, pelvic lymphadenectomy and peritoneal biopsies was performed. Histopathological examination showed no evidence of neoplasia. The patient is doing well, is being followed up at the outpatient clinic at this service, with normal imaging tests and serial tumor markers.

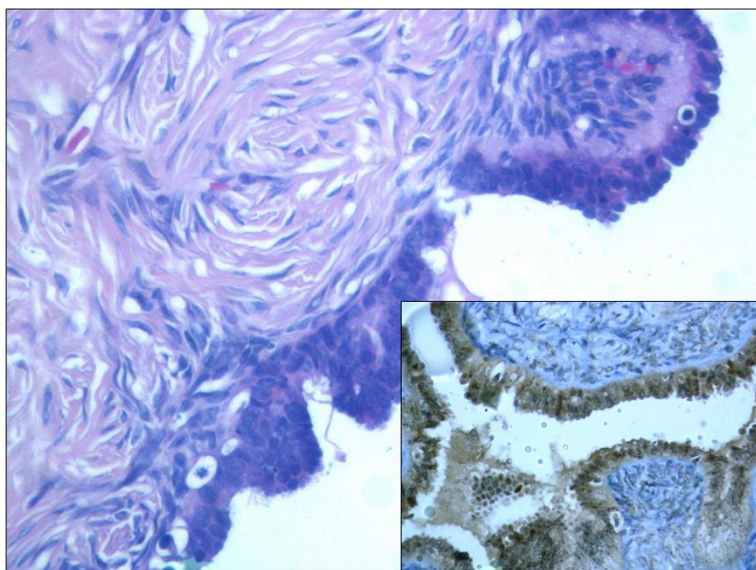


Figure1. *Histological section of fallopian tube showing lining epithelium with caryomegalia, hyperchromasia, stratification and nuclear overlap (HE, 400X) next to histological section of the same region showing positivity for anti p53 antibody in the lining epithelium (Polymer technique, 400X).*

3. DISCUSSION

Borderline fallopian tube tumors are rare and there are few reports in the literature. According to Kobayashi et al. (2017), there were 21 previously reported cases of borderline tube tumors, of which 15 were serous, five were mucinous, and one was endometrioid [4]. According to Seamon LG et al. (2009), the age of the patients ranged from 19 to 47 years, with a mean age of around 31 years. Most of the tumors occurred in young women, although some occurred in postmenopausal women, as in our patient [5].

Patients often have abdominal pain, while the others had asymptomatic masses that were discovered during routine pelvic examination. Generally, there is no evidence of peritoneal dissemination and most women can undergo conservative peritoneal surgery. In most cases, no metastasis or recurrence occurs in the follow-up [4,5]. Our patient had only sporadic

pelvic pain and dyspareunia, and has no signs of tumor recurrence or metastasis.

In a literature review by Kobayashi et al. (2016), in ten of 21 cases, the preoperative diagnosis was an ovarian or adnexal tumor. Only three patients were diagnosed preoperatively as primary fallopian tube disease [4]. Many cases have been reported in the literature as giant tumors, the largest of which was reported by Choi et al. (2014), reaching 23cm ×21cm ×9 cm, occupying a large part of the abdominal cavity [1]. Kayaalp et al. (2000), reported a 13cm ×10cm ×10cm borderline serous tumor of the fallopian tube. In other cases, the size of the tumor measures less than 10 cm [6]. In our case report, the tumor was not macroscopically visible.

Ondic et al. (2011) reported a case with non-invasive peritoneal implants, being performed bilateral salpingo-oophorectomy, hysterectomy, infracolicomentectomy and peritonectomy

omy in rectouterine reflection. There are no reports in the literature on recurrence or metastatic disease of a borderline fallopian tube tumor. Conservative fertility-preserving surgery proved to be a safe and equally effective treatment for patients who wanted to preserve their reproductive potential [3]. The patient in our report was submitted to a surgical enlargement, as she was already in menopause, without benefits in the conservative approach, given that borderline tumors still do not have a well-defined evolution and treatment.

In conclusion, we had a rare case of a borderline fallopian tube serous tumor coexisting with a contralateral ovarian cystadenoma, no case report reviewed had these two concomitant tumors. Additional studies on these types of tumors are needed, not only to establish standard treatments, but also to better understand their pathogenesis.

4. ACKNOWLEDGEMENT

The authors wish to acknowledge the funding received from the CNPq (Conselho Nacional de Desenvolvimento Científico e Tecnológico), FUNEPU (Fundação de Ensino e Pesquisa de Uberaba), FAPEMIG (Fundação de Amparo à Pesquisa do Estado de Minas Gerais), and CAPES (Coordenação de Aperfeiçoamento de Pessoal de Nível Superior - Brasil).

5. CONSENT

Consent was obtained from the patient. The study was approved by the Research Ethics Committee (protocol number 62195816.3.00.00.5154).

REFERENCES

- [1] Choi S.M., Choi M.Y., Kang WD, et al, Serous borderline tumor of the fallopian tube, *Obstet. Gynecol. Sci.* 57(4):334-7 (2014).
- [2] Abreu R., Dick M., Simões Silva T., et al. Serous borderline tumor of the fallopian tube presented as an adnexal mass, *Arch. Gynecol. Obstet.*, 283(2):349-52 (2011).
- [3] Ondic O, Kalis V andSima R. Borderline papillary serous tumor of the fimbriated end of the fallopian tube with peritoneal implants, *J. Obstet.Gynaecol.Res.* 37(11):1702-5 (2011).
- [4] Kobayashia H. andKawaia M. Tubal Serous Borderline TumorWith Strongly Positive p53 Which Developed in a 50-Year-Old Woman, *J.Clin. Gynecol. Obstet.* 6:17-22 (2017)
- [5] Seamon L.G., Holt C.N., Suarez A., Richardson D.L., Carlson M.J. and O'Malley DM. Paratubal borderline serous tumors, *Gynecol.Oncol.* 113(1):83-5 (2009).
- [6] Kayaalp E., Heller D.S. andMajmudar B. Serous tumor of low malignant potential of the fallopian tube, *Int. J. Gynecol.Pathol.* 19 (4):398-400 (2000).

Citation: *Marcela Maluf Sanguinete, Loren Géssica Santos, Eddie Fernando Candido Murta, Renata Margarida Etchebehere, Rosekeila Simões Nomelini. "Borderline Serous Fallopian Tube Tumor Coexisting with Serous Cystadenoma in Contralateral Ovary" ARC Journal of Clinical Case Reports, , vol 9, no.1, 2023, pp. 19-21. DOI: <https://doi.org/10.20431/2455-9806.0901005>*

Copyright: © 2023 Authors. This is an open-access article distributed under the terms of the Creative Commons Attribution License, which permits unrestricted use, distribution, and reproduction in any medium, provided the original author and source are credited.