

## Solitary Fibrous Tumor / Naso-sinus Hemangiopericytoma: Diagnostic and Therapeutic Management

Fatima Safini\*<sup>1</sup>, Asmaa Naim<sup>2</sup>, Zineb Bouchbika<sup>3</sup>, Bouchra Amaoui<sup>1,4</sup>, Hicham El Attar<sup>5</sup>

<sup>1</sup>Department of radiotherapy, Regional Oncology Center of Agadir, Morocco.

<sup>2</sup>Casablanca Cancer Center, Radiotherapy Department, Cheikh Khalifa International University Hospital, Casablanca, Morocco; Mohammed VI University of Health Sciences (UM6SS), Casablanca, Morocco

<sup>3</sup>Department of Oncology and Radiotherapy, CHU Ibn Rochd, Casablanca, Morocco,

<sup>4</sup>Bouchra Amaoui, Department of Radiotherapy, Faculty of Medicine and Pharmacy of Agadir, Ibn Zohr University, Morocco

<sup>5</sup>Moulay Driss Premier Anatomopathological Study Laboratory, Casablanca, Morocco

**\*Corresponding Author:** Fatima Safini, Department of radiotherapy, Regional Oncology Center of Agadir, Morocco

**Abstract:** The Hemangiopericytoma is a perivascular tumor with uncertain malignant potential. The nasosinus location is rare and differs from other locations by its low grade and its highest rate of recurrence. We report the case of a hemangiopericytoma of the nasal cavity in a 46-year-old patient, diagnosed with locally advanced stage with bone destruction and right blindness. Surgical excision was impossible. The patient received exclusive radiotherapy using intensity modulated radiation therapy and a dose of 70 Gy was delivered. After one year, the patient presented a local progression of the tumor, which required reirradiation by stereotaxic radiotherapy and received systemic chemotherapy.

**Keyword:** Hemangiopericytoma, solitary fibrous tumor, nasal cavity, diagnoses, treatment,

### 1. INTRODUCTION

Hemangiopericytoma (HP) It is a vascular tumor that starts from pericytes, cells located in the walls of capillaries. It was first described by Stout and Murray in 1942 [1]. It is a tumor that has great histopathological similarities to solitary fibrous tumors (TFS). TFS is a spindle cell tumor of mesenchymal origin, originally described by Wagner in 1870 and Klemperer in 1931 [2]. It usually occurs in the pleura but can also start in the head and neck, including the nasosinus cavity [1,2].

Thus, these two histological entities have led to much debate among pathologists to determine the best way to differentiate between TFS and HPC given the great histopathological and clinical similarities and the lack of clear diagnostic criteria [3]. Also, at the molecular level, fusion abnormalities of the NAB2-STAT6 genes and over expression of STAT6 have been identified in both TFS and HPC.

Based on all these data, these two previously separate entities have been unified into a

single entity in the new WHO classification of soft tissue and bone thus creating a new concept which is the solitary fibrous tumor / hemangiopericytoma (TFS / HP) [4,5].

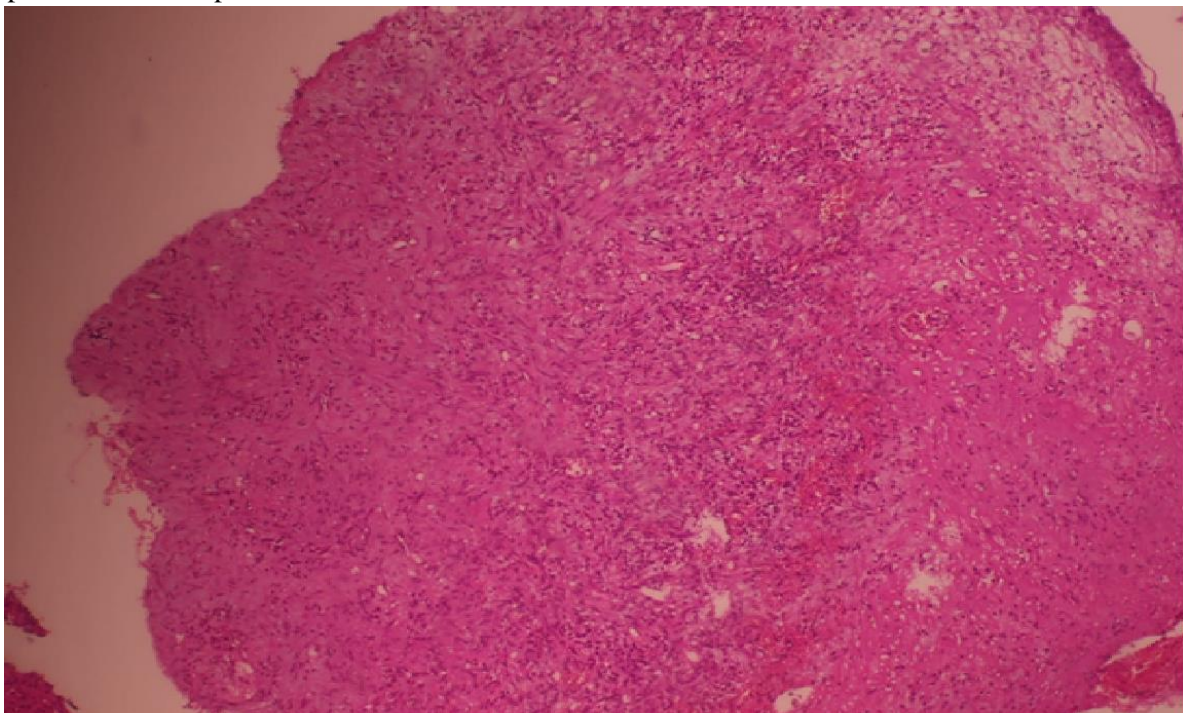
It is a tumor characterized by its slow progression, its potential for local invasion and destruction of adjacent structures [1]. It is found in 15% of cases in the head and neck region and the nasosinus location is rare [5,6]. We describe the case of a locally advanced inextirpable large TFS / HP of the nasal cavity initially treated with exclusive radiotherapy.

### 2. CASE REPORT

This is a 46-year-old man, married and father of 5 children, with no particular pathological history, whose history of the disease dates back to 8 months before the diagnosis by the progressive installation of a unilateral right nasal obstruction associated with epistaxis aggravated by exophthalmos and right blindness. All of this evolving in a context of conservation of the general condition. The clinical examination revealed a right nasal

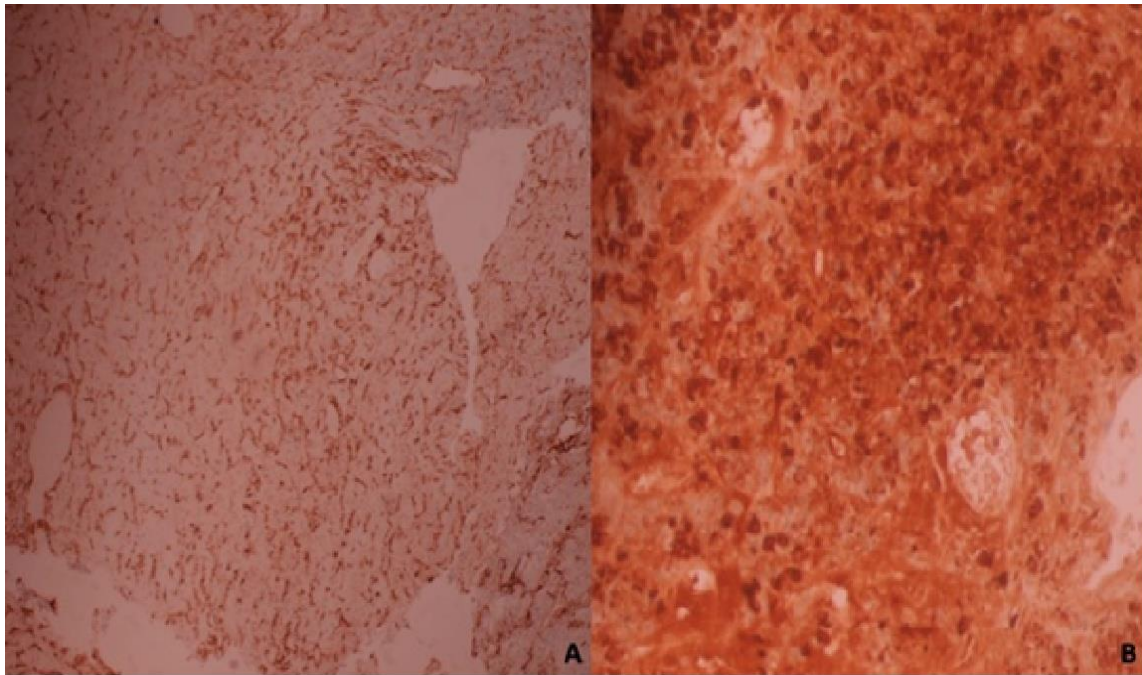
obstruction with significant swelling of the nose especially on the right, a filling of the right suborbital region and a significant right exophthalmos. The previous rhinoscopic examination had revealed a huge budding mass bleeding on contact obstructing the right nasal cavity. A biopsy was performed. Pathological examination revealed a tumor proliferation made up of thick-walled vascular elements surrounded by fibro-collagen tissue. The cells are small in size, with round nuclei and little poorly demarcated cytoplasm. we notice the presence of areas of necrosis (Figure 1). The immunohistochemical study had objectified a positivity of vimentin and CD34 (figure 2), with a negativity of HMB45, PS100 and CK. The pathological study had concluded in a SFT/hemangiopericytoma. The blonde scan and facial magnetic resonance imaging (MRI) revealed a large nasosinus process measuring  $80 \times 60 \times 47$  mm occupying the right nasal fossa, the ipsilateral maxillary sinus and the ethmoid region. This mass extended to the right para-orbital and eroded the inner wall of the right orbit resulting in grade II right exophthalmos with a contact with the right optic nerve. The lesion exceeded the midline and extended to the left nasal fossa and upwards to the posterolateral wall of the

nasopharynx with osteolysis of the bones of the base of the skull and the right pterygoid process (Figure 3). An ophthalmologic examination confirmed total blindness of the right eye with a visual acuity of 0/10. Examination of the contralateral eye was normal with visual acuity of 7/10. The case was discussed in a multidisciplinary consultation meeting. Faced with the impossibility of surgical excision, external radiotherapy was performed at a dose of 70 Gy in conventional fractionation (2 Gy / fraction, 5 fractions / week) and in conformational radiotherapy technique with modulation of intensity (figure 4 ). The follow-up clinical examination 3 months after the end of the radiotherapy showed a clear regression of the exophthalmos. The control MRI showed a reduction in tumor size. One year after the end of treatment, the patient presented to the emergency room with significant epistaxis which required previous wicking and haemostatic treatment. The nasal sinus MRI showed tumor progression on the left side. Local reirradiation has been proposed. The patient received radiotherapy by stereotaxic technique and a systemic chemotherapy was prescribed.

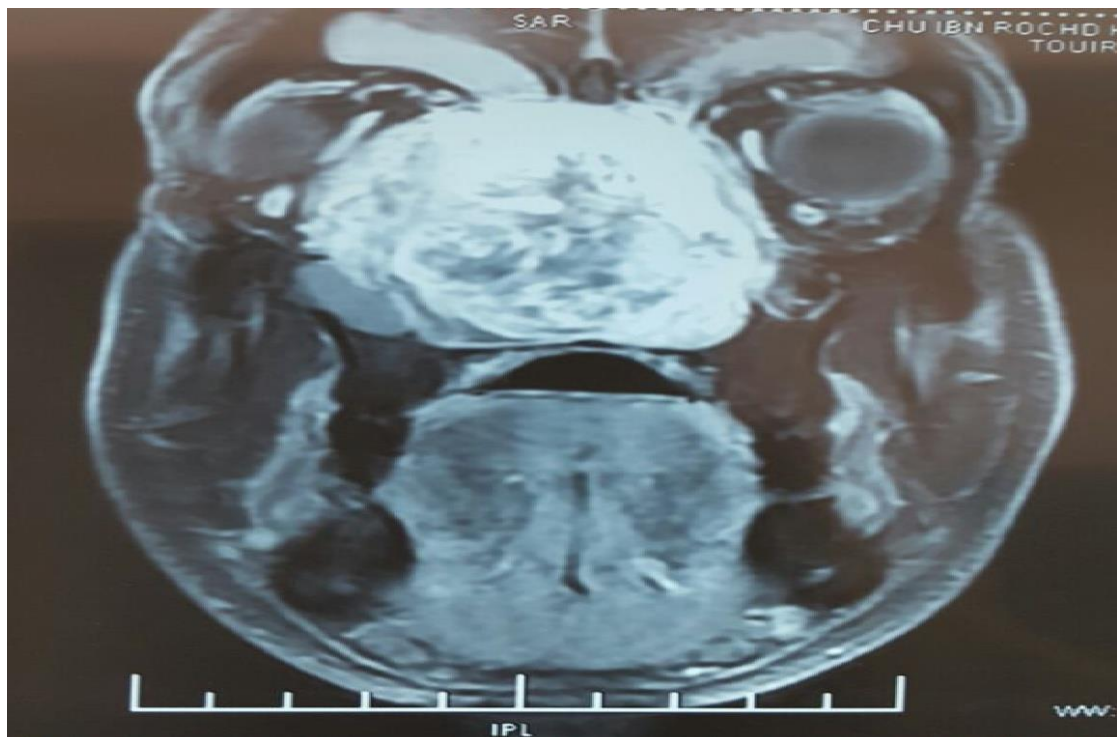


**Figure1.** Tumor proliferation made up of small, thick-walled vascular elements surrounded by fibro-collagen tissue (haematein eosin staining - G x4)

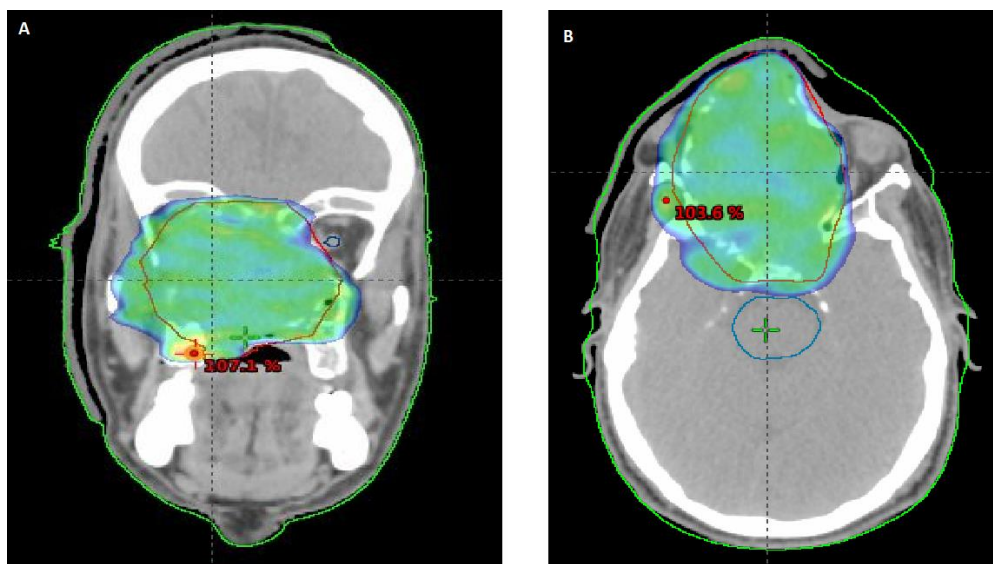




**Figure2.** (A) Diffuse cytoplasmic and membrane expression of vascular elements to anti-CD34 antibody (immunohistochemical staining - G x10) - (B) Diffuse cytoplasmic expression of tumor cells to anti-vimentin antibody confirming the mesenchymal origin (immunohistochemical staining - G x40).



**Figure3.** Coronal MRI slice in T1 sequence after gadolinium injection: voluminous nasosinus tissue process measuring  $80 \times 60 \times 47$  mm occupying the right nasal fossa, the ipsilateral maxillary sinus and the ethmoid region and extending para-orbital.



**Figure 4.** dosimetric curve representing 98% isodose. Dose distribution (70 Gy, 2 Gy per fraction, 35 fractions) provided adequate target volume coverage.

### 3. DISCUSSION

Naso-sinus TFS / HP is a rare, slow-growing tumor that is difficult to diagnose. It accounts for 1% of all vascular tumors and about 2.5% of all nasosinus tumors [3].

Since 2013, the major progress is represented by the abolition of the term hemangiopericytoma which is replaced by the name “solitary fibrous tumor” which is preferred by most pathologists as a better term than “hemangiopericytoma”. According to the 2020 WHO Soft Tissue Classification, hemangiopericytoma is currently recognized as a solitary fibrous tumor. Arthur Purdy Stout's initial description, characterized by the recognition of tumors consisting of perivascular contractile cells, remains absolutely valid. However, in recent decades, hemangiopericytoma has become the label for unrelated lesions sharing a hemangiopericytic vascular pattern, namely the presence of dilated, branched, thin-walled blood vessels. Thus, hemangiopericytoma is now considered a cellular variant in the spectrum of solitary fibrous tumor [6].

It can occur at any age between 20 and 87 years old but is usually diagnosed in the fifth decade and without noticeable difference between the two sexes [7].

As is the case in our patient, the progression is often slow and takes several months. Thompson et al performed an analysis of the clinico-pathological characteristics in 104 cases, and concluded that an average duration

of development was 10 months (between 1 and 60 months) [7].

Unilateral nasal obstruction and recurrent epistaxis are the two most common symptoms, but other signs may occur such as headache, mucopurulent rhinorrhea or exophthalmos [7].

It is a tumor whose histological diagnosis remains difficult given the histological similarity with a broad spectrum of mesenchymal tumors which includes among others the myopericytoma / myofibroma, synovial sarcoma, malignant tumors of the peripheral nerve sheaths, sarcoma of the stroma of the endometrium and mesenchymal chondrosarcoma. The definitive diagnosis is based primarily on the immunohistochemical study. Unfortunately, there are no specific markers for TFS / HP sinonasal. Vimentin is the only marker which is almost always expressed but which remains a non-specific marker [8]. The hallmark of solitary fibrous tumors is their strong CD34 staining positivity (> 90%), however, approximately 5-10% of these tumors are CD34 negative. These tumors are generally negative for cytokeratin (CK), S-100 protein, smooth muscle actin, desmin and CD117 [8,9,10]. Signal transducer and transcription activator 6 (STAT6) is a transcription factor of the Jak / STAT signal transduction pathway. Recent next-generation sequencing studies have demonstrated the presence of an NAB2-STAT6 fusion in 55-100% of solitary fibrous tumors, regardless of tumor morphology or anatomical site. Recently, it has been suggested that STAT6 is a reliable marker and will certainly improve

diagnostic accuracy by differentiating it from other soft tissue tumors. Nuclear expression on immunohistochemistry will reflect the presence of a NAB2-STAT6 gene fusion that is characteristic of these tumors. The sensitivity of STAT6 labeling exceeds 95% for the diagnosis of TFS / HP with even a high specificity exceeding 98%. Indeed, the nuclear expression of STAT6 seems highly specific for TFS / HP whereas only in 2% of cases, certain mesenchymal tumors such as fibrous histiocytoma, desmoid tumor and dedifferentiated liposarcoma can present both positivity nuclear and cytoplasmic, rather than just nuclear expression observed in TFS / HP [11].

The criteria for malignancy are still the subject of debate among pathologists. Indeed, the determination of the grade of these tumors remains controversial to date and several grading systems have been proposed. Mitotic index is the most commonly reported pathological feature to distinguish benign or low grade tumors from malignant or high grade tumors. More than 4 mitoses per high power microscopic field defines an aggressive tumor with local recurrence or metastatic extension. Some people use Ki-67 to determine the degree of aggression, but the majority of authors consider Ki-67 to be an unreliable prognostic factor [12].

The initial radiological assessment including a CT scan and / or amagnetic resonance imaging (MRI) of the rhinosinus cavities is necessary for the assessment of locoregional extension of the tumor in order to identify its exact limits and its degree of aggressiveness and invasion of neighboring structures, which may contraindicate surgical resection.

Magnetic resonance imaging (MRI) Magnetic resonance imaging (MRI) is indicated for diagnostic orientation and also for locoregional extension workup. These lesions are generally homogeneously iso-intense on the T1-weighted images and heterogeneous iso-intense or hypointense on the T2-weighted images. A predominantly weak signal on T2-weighted images is important in the diagnosis of TFS / HP as it is unusual in other nasal lesions. Sometimes hyperintensity areas can be found on T2-weighted sequences due to either hemorrhage, myxoid transformation, cystic degeneration or the presence of relatively fresh fibrous tissue [13]. There are no radiological criteria pointing to the malignancy of TFS /

HP except the discovery of a distant synchronous metastasis, a rare situation [7].

The therapeutic management depends on the initial clinical stage and the degree of tumor aggressiveness. Surgery is the treatment of choice for nasosinus TFS / HP [14,15]. Complete resection significantly improves recurrence-free survival. This surgery can be open or endoscopic. In recent years, endoscopic resection has been used more and more and has become an alternative to open resection. Indeed, data from the systematic review by Dahodwala et al of 128 cases did not find any difference between open and endoscopic resection [15].

However, the significant risk of intraoperative bleeding must be taken into account during the endoscopic approach, without forgetting that this technique often makes the pathological assessment of the margins difficult.

in our case, which presented a very important locoregional extension making surgical treatment impossible, the decision of the multidisciplinary consultation meeting was to carry out exclusive radiotherapy.

Radiotherapy is a therapeutic modality whose effectiveness remains uncertain because TFS / HP is theoretically considered to be a radio-resistant tumor [14]. Few cases reported in the literature have received radiotherapy alone or in combination with other therapeutic modalities, which limits the evaluation of its effectiveness [3]. Despite this, radiotherapy has found its place especially as an adjuvant to surgery in situations where the resection was incomplete. Indeed, the authors suggest that adjuvant radiotherapy improves recurrence-free survival and decreases the risk of local relapse in the event of incomplete surgical excision but without influence on overall survival [14].

The exclusive radiotherapy was reserved for unresectable and aggressive HP, and showed an increase in survival which is not statistically significant. Wang et al reported a case of tumor recurrence after surgery with endocranial extension treated by exclusive radiotherapy at a dose of 70 Gy followed by 2 courses of chemotherapy of the piramycin and cisplatin type. A clear clinical and radiological improvement was noted with a follow-up of 1 year without local or metastatic relapse [16].



Chemotherapy has not shown its effectiveness. Few cases reported in the literature have benefited from this therapeutic modality. Although several chemotherapy agents have been used, there is currently no evidence for or against the use of chemotherapy to treat this type of tumor [14]. It has been considered in locally advanced aggressive forms and in metastatic forms [14,15]. Indeed, Wang et al recommend a treatment combining radiotherapy and chemotherapy in the case of inoperable aggressive tumors or in case of multiple recurrences. But more studies are needed to assess clinical efficacy and the impact of chemotherapy on survival [16].

TFS / HP is generally a tumor with a good prognosis if surgical resection is complete. Nasosinus TFS / HPs are considered to be a separate entity from other locations. They have a less aggressive course with fewer distant metastases but with a higher local recurrence rate of up to 60%, explained by the anatomical complexity of this region which often makes complete resection very difficult. The so-called malignant tumors with aggressive behavior are rare and are usually large tumors responsible for bone invasion. An age  $\geq 55$

#### REFERENCES

- [1] Stout AP, Murray MR. Hemangiopericytoma: a vascular tumor featuring Zimmermann's pericytes. *Ann Surg* 1942;116:26–33.
- [2] Klemperer P, Rabin CB. Primary neoplasms of the pleura: a report of five cases. *Arch Pathol* 1931;11:385-412
- [3] Sung KS, Moon JH, Kim EH, Kang SG, Kim SH, Suh CO, Kim SH, Lee KS, Chang WS, Chang JH. Solitary fibrous tumor/hemangiopericytoma: treatment results based on the 2016 WHO classification. *J Neurosurg*. 2018 Mar 1:1-8.
- [4] Demicco EG, Park MS, Araujo DM, et al. Solitary fibrous tumor: a clinicopathological study of 110 cases and proposed risk assessment model. *Mod Pathol*. 2012; 25:1298–1306.
- [5] Gengler C, Guillou L. Solitary fibrous tumour and haemangiopericytoma: evolution of a concept. *Histopathology* 48:63–74, 2006.
- [6] Sbaraglia M, Bellan E, Dei Tos AP. The 2020 WHO Classification of Soft Tissue Tumours: news and perspectives. *Pathologica*. 2021 Apr;113(2):70-84.
- [7] Nicolas Penel, Eric Yaovi Amela, Gauthier Decanter et al. Solitary fibrous tumors and so-called hemangiopericytoma. *Sarcoma*. 2012; 2012:690251.

years, a tumor size  $\geq 10$  cm, positive surgical margins, the presence of histological necrosis and a number of mitoses  $\geq 4$  mitoses per high-power microscopic field are the predictors of recurrence and metastasis [4,12, 17].

Distant secondary localizations are exceptional. Lymph node, bone, pulmonary and hepatic metastases have been reported in high grade malignant tumors [2]. Overall 5-year survival is greater than 88% with complete tumor resection. Long-term therapeutic follow-up is recommended in order to detect relapses which may occur years later with a period of recurrence of between one and twelve years. [4].

#### 4. CONCLUSION

Naso-sinus TFS / HPs is a rare tumor with very specific histopathological and evolutionary characteristics. Surgery is the standard treatment. The other therapeutic modalities, in particular radiotherapy and chemotherapy, can lead to clinical improvement but without significant impact on survival and should not be indicated as first-line treatment except in aggressive and unresectable forms from the outset.

- [8] Han Y, Zhang Q, Yu X, Han X, Wang H, Xu Y, et al. Immunohistochemical detection of STAT6, CD34, CD99 and BCL-2 for diagnosing solitary fibrous tumors/hemangiopericytomas. *Int J Clin Exp Pathol*. 2015;8 (10):13166–75
- [9] Yokoi H, Arakawa A, Kuribayashi K, Inoshita A, Haruyama T, Ikeda K. An immunohistochemical study of sinonasal hemangiopericytoma. *Auris Nasus Larynx*. 2011 Dec;38(6):743-6.
- [10] Tadashi Terada, Tanji Kato. Sinonasal-type hemangiopericytoma of the nasal cavity and paranasal sinus. *Int J Clin Oncol* (2012) 17:169-173.
- [11] Thompson LDR, Lau SK. Sinonasal tract solitary fibrous tumor: a clinicopathologic study of six cases with a comprehensive review of the literature. *Head Neck Pathol*. 2018;12(4):471-80.
- [12] Luke Stanisce, Nadir Ahmad, Kristin Levin, Nathan Deckard. Solitary Fibrous Tumors in the Head and Neck: Comprehensive Review and Analysis. *Head Neck Pathol* 2020 Jun;14(2):516-524
- [13] BT Yang, Z.L. Song, Y.Z. Wang et al. Solitary fibrous tumor of the sinonasal cavity: CT and MR imaging findings. *AJNR Am J Neuroradiol* 2013 ;34(6):1248-51.

- [14] Duval M, Hwang E, Kilty SJ. Systematic review of treatment and prognosis of sinonasal hemangiopericytoma. *Head Neck*. 2013 Aug;35(8):1205-10.
- [15] Dahodwala MQ, Husain Q, Kanumuri VV, Choudhry OJ, Liu JK, Eloy JA. Management of sinonasal hemangiopericytomas: a systematic review. *Int Forum Allergy Rhinol*. 2013 Jul;3(7):581-7.
- [16] Wang X, Wang J, Hu W, Wang L, Li Y. Combined therapy against recurrent and intracranial invasion of sinonasal hemangiopericytoma: A case report. *Oncol Lett*. 2015 Jul;10(1):287-290.
- [17] Steven C. Smith, William E. Gooding, Matthew Elkins, Rajiv M. Patel et al. Solitary Fibrous Tumors of the Head and Neck: A MultiInstitutional Clinicopathologic Study. *Am J Surg Pathol*. 2017 Dec; 41(12):1642-1656.

**Citation:** Fatima Safini et al. "Solitary Fibrous Tumor / Naso-sinus Hemangiopericytoma: Diagnostic and Therapeutic Management ", *ARC Journal of Clinical Case Reports (ARCJCCR)*, vol. 8, no.1, pp. 1-7, 2022. <http://dx.doi.org/10.20431/2455-9806.0801001>

**Copyright:** © 2022 Authors. This is an open-access article distributed under the terms of the Creative Commons Attribution License, which permits unrestricted use, distribution, and reproduction in any medium, provided the original author and source are credited.