

Tropical Spastic Para Paresis and Ayurveda

Dr Avinash Shankar^{1*}, Dr Amresh Shankar², Dr Anuradha Shankar³

¹MBBS(MGIMS); MD (Internal Medicine); DNB(E&M); PhD, Postgraduate in Endocrinology & Metabolism (AIIMS Delhi), Chairman, National Institute of Health & Research, Warisaliganj (Nawada) Bihar India

²BAMS(BRABU); MHA, Director (Hon), Aarogyam Punarjeevan, Ram Bhawan, Ara Garden Road, Jagdeopath, Baily Road, Patna 14, India

³BAMS (BRABU), Ex Director, Centre for Indigenous Medicine & Research, Senior Research Fellow, Regional Institute of Ayurveda, Itanagar, Arunachal Pradesh, India

***Corresponding Author:** Dr Avinash Shankar, PhD Postgraduate in Endocrinology & Metabolism (AIIMS Delhi), Chairman, National Institute of Health & Research, Warisaliganj (Nawada) Bihar India.
Email: dravinashshankar@gmail.com

Abstract: Tropical spastic para paresis a disease of nervous system is caused by Human T lymphotropic virus type I thus also known as HTLV-I associated myelopathy and common among female of age group 30-50 years in approximately 2-3% of HTLV-1 affected person.

In spite advancement in diagnostic procedure i.e.-CTscan, MRI its treatment remain a challenge to ensure cure and better quality of life, thus a composite consisting a proven herbal neurogenic been evaluated

Object of Study: To assess the herbal neurogenic and immune boosting composite in ensuring clinical relief and improving quality of life in patients deterred from various medi centres without any relief.

Material & Method: 63 diagnosed and already treated cases of Tropical spastic para paresis attending at Centre for Critical Care National Institute of Health & Research Warisaliganj (Nawada)Bihar been selected, interrogated, examined clinically, assessed and analysed their previous investigation reports, therapeutics taken and their effect.

Irrespective of their clinical severity all patients were dvocated the prescribed regime and were followed for post therapy 2 years for which patients been given a follow up card to record the changes.

Result: 88.9% patients had grade I clinical response while rest 11.1% grade II without any untoward effect or any withdrawal during post therapy 2 years follow up.

Keywords: Tropical spastic para paresis, Human T lymphotropic virus –type I, CT, MRI, herbal neurogenic

1. INTRODUCTION

Tropical spastic para paresis, a chronic and progressive clinical condition affecting Nervous system remained of obscure etiopathogenesis for long but now a days an important association of this condition been established between Human retrovirus (Human T cell lymphotropic virus type I) thus this condition is also termed as HTLV1 associated myelopathy (HAM).

As per W.H.O. estimate worldwide 10-20 million peoples are carrying HTLV1 and 5% of it are affected with TSP of age group 30-50 years[1-10]

TSP is very common in Latin America, the Caribbean Basin, sub-Saharan Africa and Japan but these days incidence of this clinical state is increasing even in India.

Common presentation of the clinical condition is – [11-14]

- Gradual weakening and stiffening of lower extremity
- Raditing bakck pain down to legs
- Burning and pricking sensation (paraesthesia)
- Urinary and bowel function disturbances
- In male erectile dysfunction
- Inflammatory skin condition like dermatitis or psoriasis
- Rarely may present with eye inflammation, arthritis, and muscle inflammation

The common mode of transmission of this virus is through – [15-16]

- breastfeeding
- sharing infected needles during intravenous drug use
- sexual activity

- blood transfusions

In spite of advancement in diagnostics (CT scan and MRI) and its established etiopathogenesis till date no established therapeutic regime ensured its reversal but only symptomatic relief, ie- alpha interferon, intravenous immunoglobulin, antiviral drugs and muscle relaxants Tizanidine

Signs and symptoms vary but may include slowly progressive weakness and spasticity of one or both legs, exaggerated reflexes, muscle contractions in the ankle, and lower back pain. Other features may include urinary incontinence and minor sensory changes, especially burning or prickling sensations and loss of vibration sense.

Considering the poor quality of life with present therapeutics a clinical study was planned to evaluate the clinical efficacy of proved neurogenic herbal composite with neuro modulator at National Institute of Health & Research and Centre For Research in Indigenous Medicine.

2. OBJECTIVE OF THE STUDY

To evaluate the clinical efficacy and safety profile of herbal neurogenic with neuromodulator in TSP.

Severity Grade	Characteristics
Mild	Patients presenting with back pain, tingling and numbness in the leg
Moderate	Patient presenting with back pain, tingling numbness, tendency to fall Heaviness in the lower extremity, leg weakness
Severe	Back pain, gait disturbance, stumbling, leg weakness, hyper reflexia, plantar Extensor, overactive bladder, constipation and sexual dysfunction

Patients were investigated for hemoglobin concentration, total and differential leucocyte count, erythrocyte sedimentation rate (ESR),

3. MATERIAL & METHODS

Material: Patients of proved and treated cases of Tropical spastic Para paresis without any clinical response, attending at Centre for Critical Care, National Institute of Health & Research were considered for evaluation of the herbal neurogenic constituting therapeutic regime.

Methods: Patients of spastic para paresis diagnosed by myelogram, computerized tomography(CT) and magnetic resonance imaging (MRI) been interrogated thoroughly for the onset, duration and evolution of the disease, Family history of neurological illness, history of extramarital sexual exposure, abortion, blood transfusions, dietary with emphasis on strict vegetarianism, Lathyrus sativus, Socio-economic status, housing, sanitary conditions, treatment taken and their response. A detailed general examination and a meticulous neurological assessment were done.

Based on clinical presentation patients were classified as –

peripheral smear, fasting and postprandial blood sugar, renal and liver function tests, and serological test for syphilis. Common presentation of TSP can be summarized as –

Disturbances	Symptoms	Signs
Motor	Gait disturbance, tendency to fall Stumbling and leg weakness	Spastic para paresis, weakness hyperreflexia lower limb, clonus
Sensory	Pain ,numbness at lumbar level And backache	Plantar extensor feet paresthesia, loss of light touch sensory level at lower thoracic level
Autonomic	urinary dysfunction, constipation Sexual dysfunction	neurogenic or overactive bladder diminished peristalsis Erectile dysfunction

All patients underwent conventional myelography CT and MRI scans. The serum samples of all the patients were tested for HTLV-1 antibodies by the serodia technique.

All patients presenting with this crippling disease were advised and administered the following therapeutic regime after due awareness counselling and encouragement –

Inj Calcium gluconate 1amp every 15th day intravenous very slow
Inj Methyl cobalamine +Pyridoxin +Niacinamide +Pantothenic acid + Betamethasone every week
Inj Self blood +Betamethasone 2mg every 10th day intramuscular
Cap Vitamin D3 60 K every week orally
Syrup NEUROVIT 10 ml every 12 hours /Cap NEUROVIT 1 cap every 12 hours
Active and passive exercise of the extremity
Diet: High Protein vegetarian diet

Herbal composite NEUROVIT Syr or Capsule constitutes – Cap 500mg or Syr. 5ml constitutes

100mg each of Acorus calamua(rhizome), Nardostachys jatamansi(Flower), Herpestis

monnieri (leaf), Convolvulus pluricaulis (flower), Cassia acutifolia (seed)

Patients were assessed for improvement in tone and power of the muscle, tingling and numbness, gait, and autonomic function (passage of stool and urine) for which patients were given a follow up card to mention date of achievement and any untoward manifestation experienced. Patients were advised to visit the center on any unusual manifestation or contact on helpline for needful redresses.

To adjudge the safety profile of the regime practiced basic bio parameters were repeated every month for first three month and then every 3 months.

Based on the clinical outcome and safety profile therapeutic response was graded as –

Clinical Grade	Characteristics
Grade I	Complete recovery of power and tone without any Residual neurological deficit and adversity
Grade II	Improvement in power and tone with residual paresis and sensory deficit without any adversity
Grade III	No alteration in status

4. RESULT

63 identified, diagnosed and treated Patients of Tropical spastic para paresis considered for study were of age group 30-50 years and out of them majority (30/63) were of age group 30-35 years with female dominance (Table-1, Figure - 1) and all were from rural background and community representation was (figure 2)

Table1. Shows distribution of patients as per age & sex

Age Group (In years)	Number of Patients		
	Male	Female	Total
30-35	02	28	30
35-40	04	12	16
40-45	-	06	06
45-50	-	11	11

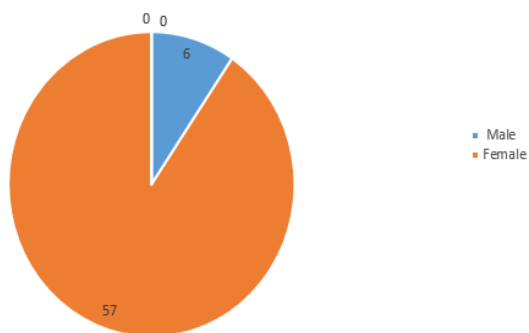


Figure1. Pie diagram showing Male: Female composition

Distribution as per community

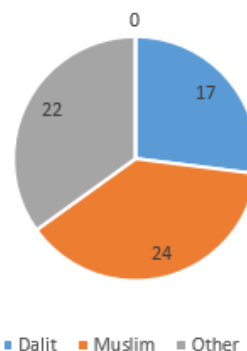


Figure2. Pie diagram showing distribution of patients as per community

Out of all majority were non vegetarian and non had any history of taking *Lathyrus sativus*. (figure -3)

Pie diagram showing distribution of patients as per dietary status

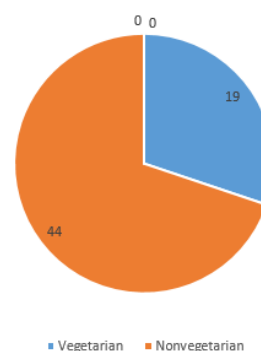


Figure3. Pie Diagram Showing Dietary Status

The age of onset of clinical presentation varied from 20-40 years and duration of illness from 1 year to 12 years (Figure-4)

Bar diagram showing distribution of patients as per duration of illness

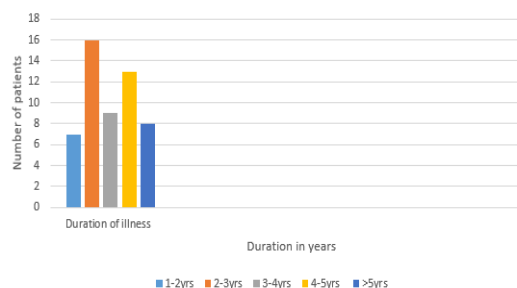


Figure4. Bar Diagram Showing Distribution of Patients as Per Duration of Illness

Symptoms at the onset were difficulty in walking, stiffness of legs, back pain, weakness of legs, leg pain and urinary discomfort (Table-) while presenting presentation at our center were disturbed gait, leg stiffness, back pain, leg pain urinary discomfort, urinary retention, tingling and numbness, erectile deficiency in male cases. (Table -2)

Table2. Showing Distribution of Patients as Per Their Clinical Presentation

Clinical Presentation	Number of Patients
Difficulty in walking	63
Leg Stiffness	63
Back Pain	43
Weakness of the legs	63
Leg Pain	63
Tingling and Numbness	63
Gait Disturbance	50
Urinary Discomfort	50
Sexual Weakness	06
History of surgery, abortion and blood transfusion	None

No history of blood transfusion, abortion, delivery or surgery prior to onset of the disease but serum samples revealed positive for HTLV-1 in 49 cases out of 63. In addition all the bio parameters (Hepatic, hematological and renal profile remain normal) (Figure -5)

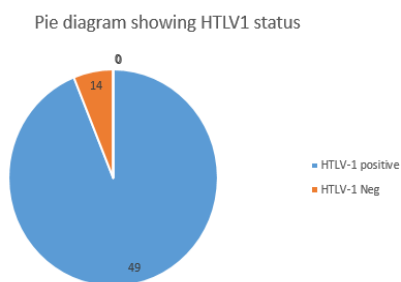


Figure5. Pie Diagram Showing HTLV-I Status of the Patients

No patients were positive for Tuberculosis, any sexually transmitted disease, CT and MRI also shows normal in all the cases, Out of 63 patients 13 were of moderate and 50 were of severe status (Figure-6)

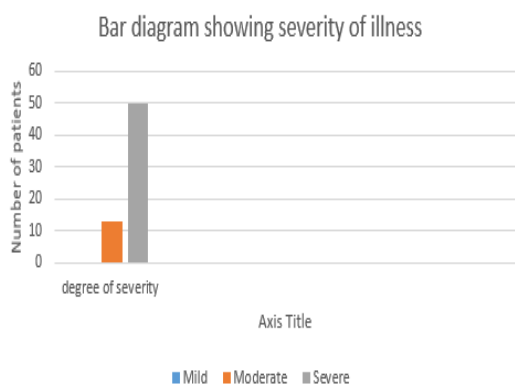


Figure6. Bar Diagram Showing Clinical Severity

Patients had taken treatment with α interferon, muscle relaxants, neuro vitamin supplementation at various medicare centers without any positive therapeutic outcome. (Table-3)

Table3. Showing Treatments Taken in Past

Therapeutics Taken	Number of Patients
Alpha Interferon	43
Antiviral Drug	49
Muscle Relaxants	63
Neurovitamin Supplement	63
Active & Passive Exercise	63

Symptomatic relief started from 4th week of therapy and by 24th week all had symptomatic relief (Figure -7)

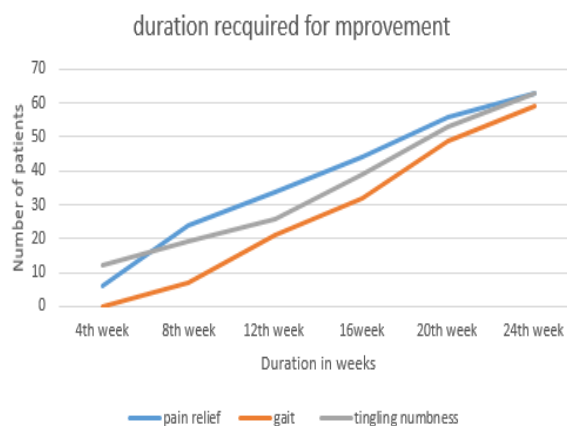


Figure7. Graph Showing Duration Required for Improvement in Presentation

The minimum and maximum duration of therapy required for complete reversal of clinical presentation (both symptom & sign) is 9 months and 2 years respectively

Out of all 56 patients achieved Grade I clinical improvement and 7 Grade II(Figure-8)

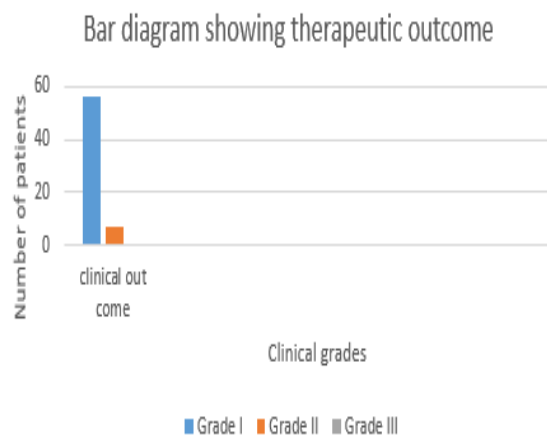


Figure8. Bar Diagram Showing Grades of Clinical Response

No patients shown any adversity, recurrence of presentation or any alteration in bio parameters in 2 years of post therapy follow up. (Table -4)

Table4. Showing Outcome of the Study

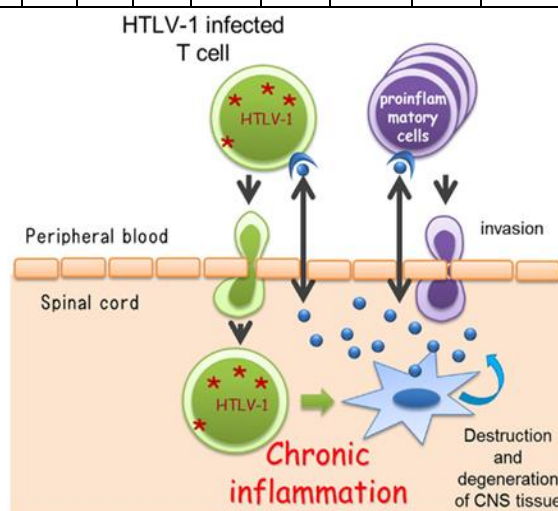
Particulars	Number of Patients									
	1	2	3	4	5	6	9	12	24	
Duration in months	1	2	3	4	5	6	9	12	24	
Clinical Relief	6	24	34	44	56	63	63	63	63	
Back Pain	14	24	32	45	63	63	63	63	63	
Tingling Numbness	12	19	26	39	53	63	63	63	63	
Pain in legs	12	21	24	37	48	63	63	63	63	
Autonomic Disturbance	-	-	19	30	42	50	63	63	63	
Gait	-	4	14	22	32	50	63	63	63	
Post therapy bio parameters Hepatic Profile										
SGOT<35IU	63	63	63	63	63	63	63	63	63	
SGPT<35IU	63	63	63	63	63	63	63	63	63	
Alkaline Phosphatase<100	63	63	63	63	63	63	63	63	63	
Renal Parameters										
Blood Urea<26mg%	63	63	63	63	63	63	63	63	63	
Serum Creatinine<1.5mg%	63	63	63	63	63	63	63	63	63	
Urine										
Albumin –Negative	63	63	63	63	63	63	63	63	63	
RBC-Negative	63	63	63	63	63	63	63	63	63	
Haematological										
Haemoglobin >10gm%	52	58	59	63	63	63	63	63	63	
Clinical grade										
Grade I									56	
Grade II									07	
Grade III										

5. DISCUSSION

Tropical spastic para paresis is also common neurological disorder in India though it's a common in different parts of the world i.e.- including Jamaica, Martinique, Seychelles, Colombia and Japan. Though it was considered as a neurological disorder of obscure etiology but these days it is proved to be caused by Human T cell lymphotropic virus type I (HTLV-I). In spite of advancement in diagnostics like CT, MRI, CSF and Serum for HTLV-I antigen [18,19], the therapeutics used i.e. alpha interferon, muscles relaxant and neuro vitamin supplement [20,21,22] fails to ensure cure or improve quality of life except transient symptomatic relief.

Clinical supremacy in term of marked improvement in pain, sensation and gait of the already treated patients with other regime and achieving Grade I clinical response in 88.9% patients and Grade II in rest 11.1%. No patients had any withdrawal or drug adversity in 2 years post therapy follow up.

This clinical efficacy can be explained as- Considering its pathogenesis and caused due to HTLV-I infected T cells



Self- blood with Betamethasone intramuscular induces antibody formation against the released toxin and ensure their neutralization while betamethasone acting as anti-inflammatory reduces neural edema synergized by Intravenous Calcium administration whose inclusion of one mole exit 2 mole of Sodium acting on Sodium potassium ATPase pump and facilitate decrease in neural edema and calcium ion improves neural conduction.

Methyl cobalamine, pyridoxine, Niacin and pantothenic acid support neural cells in its normal neural conduction and Neurovit a herbal

composite by its neurogenic activity helps in restoration of neural viability and vitality which combinely ensure relief in pain, neuropathic manifestation, gait and autonomic function and provide better quality of life to all

6. CONCLUSION

Present regime constituting Calcium gluconate intravenous, Methyl cobalamine +Pyridoxin+ Niacin intravenous, Self -blood (2ml) and Betamethasone 2mg intramuscular, cap Cholecalciferol 60K, Syrup Herbal neurotonic (Neurovit) proves worth in management of Tropical spastic para paresis even in chronic and long term treated cases.

REFERENCES

- [1] World Health Organization (WHO). (1989). Human T lymphotropic virus type 1, HTLV Wkly. Epidemiol. Rec. 64, 382–383.
- [2] Orland, J. R., Engstrom, J., Fridey, J., Sacher, R. A., Smith, J. W., Nass, C., et al. (2003). Prevalence and clinical features of HTLV neurologic disease in the HTLV outcomes study. *Neurology* 61, 1588–1594. Pubmed Abstract | Pubmed Full Text | CrossRef Full Text
- [3] Blattner, W. A., and Gallo, R. C. (1985). Epidemiology of human retroviruses. *Leuk. Res.* 9, 697–698. Pubmed Abstract | Pubmed Full Text | CrossRef Full Text
- [4] Oomman A, Madhusoodanan M. Tropical spastic paraparesis in Kerala, South India. *Neurol India* 2003; 51: 493-6 Year: 2003 | Volume: 51 | Issue: 4 | Page: 493-496
- [5] Roman GC. The neuroepidemiology of tropical spastic paraparesis. *Ann Neurol* 1988;23:113-20
- [6] Arango C, Concho M, Zaninovic V, Biojor, Borrero I, Rodgers, et al. Epidemiology of tropical spastic paraparesis in Colombia and associated HTLV-1 infection. *Ann Neurol* 1988;23:161-5.
- [7] Richardson JH, Newell AL, Newman PK, Mani KS, Rangan G, Dalgleish AG. HTLV-1 and neurological disease in South India. *Lancet* 1989;I:1079
- [8] Gessain A, Barin F, Vernant JC, Gout O, Calendar A, De-The G. Antibodies to human T-lymphotropic virus type I in patients with tropical spastic paraparesis. *Lancet* 1985;ii:407-10.
- [9] Rubin M. Tropical Spastic Paraparesis/HTLV-1–Associated Myelopathy (TSP/HAM). *Merck Manual*. October, 2016; <http://www.Merckmanuals.com/professional/neurologic-disorders/spinal-cord-disorders/tropical-spastic-paraparesis-htlv-1%E2%80%93associated-myelopathy-tsp-ham>
- [10] Tropical Spastic Paraparesis Information Page. *National Institute of Neurological Disorders and Stroke*. <https://www.ninds.nih.gov/Disorders/All-Disorders/Tropical-Spastic-Paraparesis-Information-Page>. Accessed 7/12/2017
- [11] Iwasaki, Y (1990) Pathology of Chronic myelopathy associated with HTLV-1 infection (HAM/TSP). *J. Neurolo. Sci.* 96, 103-123, Pubmed
- [12] Izumo, S, Umehara, F., and Osame, M (2000), HTLV-1 associated myelopathy, *Neuropathology* 20, 565-568 Pubmed
- [13] Osame, M. (2002). Pathological mechanisms of human T-cell lymphotropic virus type I-associated myelopathy (HAM/TSP). *J. Neurovirool.* 8, 359–364. Pubmed Abstract | Pubmed Full Text | CrossRef Full Text
- [14] Lezin, A., Olindo, S., Oliere, S., Varrin-Doyer, M., Marlin, R., Cabre, P., et al. (2005). Human T lymphotropic virus type I (HTLV-I) proviral load in cerebrospinal fluid: a new criterion for the diagnosis of HTLV-I-associated myelopathy/tropical spastic paraparesis? *J. Infect. Dis.* 191, 1830–1834. Pubmed Abstract | Pubmed Full Text | CrossRef Full Text
- [15] Matsuzaki, T., Nakagawa, M., Nagai, M., Usuku, K., Higuchi, I., Arimura, K., et al. (2001). HTLV-I proviral load correlates with progression of motor disability in HAM/TSP: analysis of 239 HAM/TSP patients including 64 patients followed up for 10 years. *J. Neurovirool.* 7, 228–234. Pubmed Abstract | Pubmed Full Text | CrossRef Full Text
- [16] De Castro-Costa, C. M., Araújo, A. Q., Barreto, M. M., Takayanagui, O. M., Sohler, M. P., da Silva, E. L., et al. (2006). Proposal for diagnostic criteria of tropical spastic paraparesis/HTLV-I-associated myelopathy (TSP/HAM). *AIDS Res. Hum. Retroviruses* 22, 931–935. Pubmed Abstract | Pubmed Full Text | CrossRef Full Text
- [17] Bagnato, F., Butman, J. A., Mora, C. A., Gupta, S., Yamano, Y., Tasciyan, T. A., et al. (2005). Conventional magnetic resonance imaging features in patients with tropical spastic paraparesis. *J. Neurovirool.* 11, 525–534. Pubmed Abstract | Pubmed Full Text | CrossRef Full Text
- [18] Scadden DT, Freedman AR, Robertson P. Human T-lymphotropic virus type I: Disease associations, diagnosis, and treatment. *UpToDate*. Waltham, MA: UpToDate; February 16, 2016; <http://www.uptodate.com/contents/human-t-lymphotropic-virus-type-i-disease-associations-diagnosis-and-treatment>
- [19] Sandbrink F. Tropical Myeloneuropathies Treatment & Management. *Medscape Reference*. January, 2015; <http://emedicine.medscape.com/article/1166055-treatment>
- [20] Arimura, K., Nakagawa, M., Izumo, S., Usuku, K., Itoyama, Y., Kira, J., et al. (2007). Safety and efficacy of interferon- α in 167 patients with

- human T-cell lymphotropic virus type 1-associated myelopathy. *J. Neurovirol.* 13, 364–372. [Pubmed Abstract](#) | [Pubmed Full Text](#) | [CrossRef Full Text](#)
- [21] Croda, M. G., de Oliveira, A. C., Vergara, M. P., Bonasser, F., Smid, J., Duarte, A. J., et al. (2008). Corticosteroid therapy in TSP/HAM patients: the results from a 10 years open cohort. *J. Neurol. Sci.* 269, 133–137. [Pubmed Abstract](#) | [Pubmed Full Text](#) | [CrossRef Full Text](#)
- [22] Taylor, G. P., Goon, P., Furukawa, Y., Green, H., Barfield, A., Mosley, A., et al. (2006). Zidovudine plus lamivudine in human T-lymphotropic virus type-I-associated myelopathy: a randomised trial. *Retrovirology* 3, 63. [Pubmed Abstract](#) | [Pubmed Full Text](#) | [CrossRef Full Text](#)

Citation: *Dr Avinash Shankar, Dr Amresh Shankar, Dr Anuradha Shankar, Tropical Spastic Para Paresis and Ayurveda. ARC Journal of Clinical Case Reports. 2019; 5(2): 11-17. doi:dx.doi.org/ 10.20431/2455-9806.0502004.*

Copyright: © 2019 Authors. This is an open-access article distributed under the terms of the Creative Commons Attribution License, which permits unrestricted use, distribution, and reproduction in any medium, provided the original author and source are credited.